

Meeting abstract

Open Access

2119 Visualization of micro-vasculature using FeCo-core/graphitic-carbon-shell nanocrystals and high-resolution 3D spiral imaging

Jin Hyung Lee*, Masahiro Terashima, Won Seok Seo, Hisanori Kosuge, Sarah Sherlock, Michael McConnell, Dwight Nishimura and Hongjie Daiv

Address: Stanford University, Stanford, CA, USA

* Corresponding author

from 11th Annual SCMR Scientific Sessions
Los Angeles, CA, USA. 1–3 February 2008

Published: 22 October 2008

Journal of Cardiovascular Magnetic Resonance 2008, **10**(Suppl 1):A388 doi:10.1186/1532-429X-10-S1-A388

This abstract is available from: <http://jcmr-online.com/content/10/S1/A388>

© 2008 Lee et al; licensee BioMed Central Ltd.

Introduction

Non-invasive visualization of small vessel structures has been difficult due to insufficient contrast between small vessels and background tissue, and limited spatial resolution of MRI. Here, we present a method to non-invasively visualize small vascular structures in-vivo, in live animals using novel contrast agents combined with fast, high resolution image encoding methods.

Purpose

To evaluate the use of 1) the FeCo-Core/Graphitic-Carbon-Shell nanocrystal contrast agent [1] and 2) the high resolution encoding enabled by 3D spiral acquisition and small surface coils for the visualization of microvasculature in-vivo.

Methods

Normal and stenosis induced white rabbits with body weight of ~4 kg were first catheterized in the ear vein. Through the catheter, 9.6 cc of 5 mM concentration FeCo nanocrystal contrast agent was injected followed by 1 cc of saline injection. Immediately before and after the injection, a small volume covered by a 1 inch custom made surface coil was imaged using spectral-spatial excitation and 3D spiral readout. The spatial resolution was $78 \times 78 \times 500 \text{ } \mu\text{m}^3$ with volume coverage of $4 \times 4 \times 1 \text{ cm}^3$. The scan time was 2 min 40 sec for a single volume and the scan was repeated 9 times over 24 min to improve SNR. A whole body volume scan using a fat-saturated 3D SPGR

sequence was also performed using a standard GE head coil 1 hour before and after the injection. All the experiments were conducted using a GE 1.5 T EXCITE whole body system with a maximum gradient of 40 mT/m and maximum slew rate of 150 T/m/s.

Results

The FeCo nanocrystal contrast agent's ability to produce high enhancement with 0.2 mM blood concentration which is 10% of Gd (Magnevist) dosage is demonstrated in Fig. 1. Enhancement factor of 9 is achieved (Figure 1b, c) as expected from the relaxivity parameters (Figure 1a). The aortic stenosis can also be clearly observed in Fig. 1b. With this strong enhancement and high resolution acquisition, small vessels down to 78 μm in diameter were successfully visualized in-vivo (Figure. 2b).

Conclusion

The FeCo contrast agent provides several advantages for high resolution vessel imaging; strong relaxivity, relatively long circulation time compared to conventional Gd based contrast agent, and small nano-scale size. These properties allow sufficient contrast in the small vessels for a long enough time to acquire high resolution images. The high resolution 3D spiral imaging technique combined with this FeCo contrast agent demonstrates great potential to visualize microvasculature in-vivo.

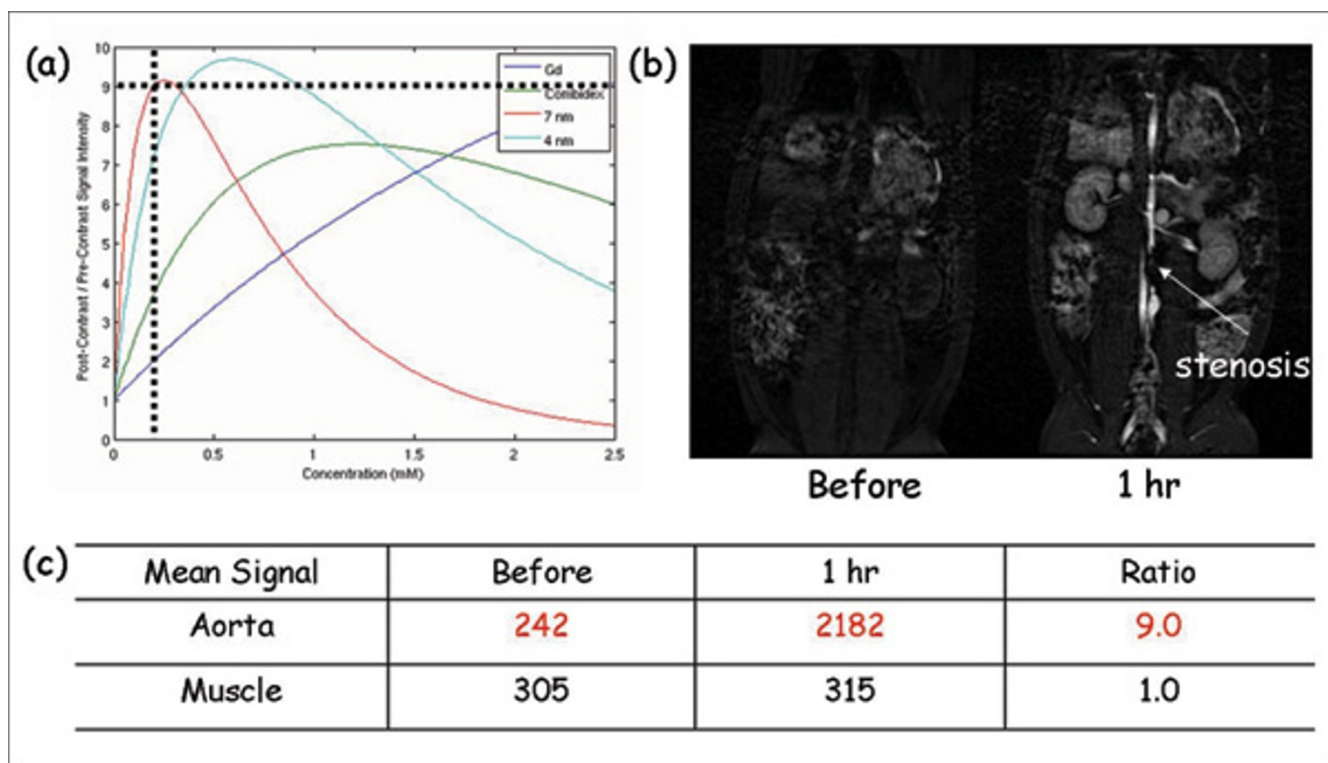


Figure 1
 The relaxivity parameters of various contrast agents indicate that with the SPGR acquisition, 0.2 mM blood concentration can produce 9 fold signal enhancement with the FeCo nanocrystal based contrast agent (a). The predictions are confirmed in (b), (c) and (b) also shows a nice depiction of the aortic stenosis.

In this paper, we present a method to non-invasively visualize small vascular structures (~78 um) in-vivo, in live animals using novel FeCo-Core/Graphitic-Carbon-Shell nanocrystal contrast agents combined with fast, high resolution 3D spiral encoding methods.

References

1. Seo WS, et al.: *Nat Mater* 2006, **5(12)**:971-6.

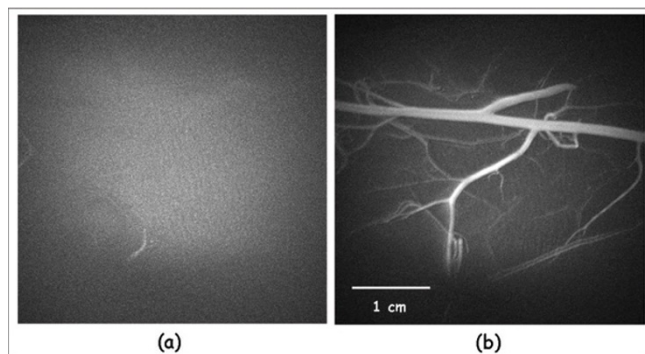


Figure 2
 Maximal intensity projection (MIP) of the vessel images in the rabbit leg (a) before contrast injection, and (b) immediately after contrast injection.

Publish with **BioMed Central** and every scientist can read your work free of charge

"BioMed Central will be the most significant development for disseminating the results of biomedical research in our lifetime."
 Sir Paul Nurse, Cancer Research UK

Your research papers will be:

- available free of charge to the entire biomedical community
- peer reviewed and published immediately upon acceptance
- cited in PubMed and archived on PubMed Central
- yours — you keep the copyright

Submit your manuscript here:
http://www.biomedcentral.com/info/publishing_adv.asp