

Poster presentation

Visualization of infarction using fractional anisotropy

Sahar Soleimanifard*, Khaled Z Abd-Elmoniem, Harsh Agarwal, Miguel S Tomas, Tetsuo Sasano, Evertjan Vonken, Amr Youssef, M Roselle Abraham, Theodore P Abraham and Jerry L Prince

Address: Johns Hopkins University, Baltimore, USA

* Corresponding author

from 13th Annual SCMR Scientific Sessions
Phoenix, AZ, USA. 21-24 January 2010

Published: 21 January 2010

Journal of Cardiovascular Magnetic Resonance 2010, **12**(Suppl 1):P153 doi:10.1186/1532-429X-12-S1-P153

This abstract is available from: <http://jcmr-online.com/content/12/S1/P153>

© 2010 Soleimanifard et al; licensee BioMed Central Ltd.

Introduction

Accurate localization of ischemia is crucial in diagnosis of myocardial disease. The zHARP[1] pulse sequence quantifies myocardial function by computing a three-dimensional strain tensor at each voxel, from which principal strain values and orientations can be computed. At systole in a normal heart, two of the principal strains are less than unity (circumferential and longitudinal compression) and the other is greater than unity (radial stretching). At this time, the strain tensor is anisotropic, and its fractional anisotropy[2] (FA), a number between 0 and 1 representing the degree of tensor anisotropy, differs markedly from zero. It is hypothesized that infarcted tissue will not elongate as much as in healthy, active muscle, and will therefore have a smaller FA. Delayed enhancement technique, based on delay in contrast uptake, is currently used to separate healthy and infarct tissue. Strain tensor shows potential for the separation without negative effects associated with contrast agent.

Purpose

To introduce a scalar index of three-dimensional regional myocardial strain for detection and localization of myocardial infarction.

Methods

Myocardial infarction (MI) was induced by LAD coronary artery ligation in a pig. Gadolinium contrast was performed after infarction and delayed enhancement (DE) viability images were acquired. The zHARP pulse

sequence was run on a commercial Philips 3T-Achieva whole body system, yielding 8-10 slices from which mid-ventricular three-dimensional strains were computed. FA was evaluated at each voxel for all time frames within one cardiac cycle. The mid-diastolic tagged images were registered to the corresponding DE images, and Harp tracking[3] was used to register the FA occurring at end-systole with the DE intensities observed on the mid-diastolic geometry.

Results

Fig. 1 shows corresponding mid-diastolic DE and FA short-axis images, where FA is taken from end-systole. Fig. 2 plots the intensity pairs (DE, FA) for high-SNR healthy and infarct regions ($r = -0.86$) as showed in Fig. 3. FA has a mean of 0.3420 and standard deviation of 0.0465 in the healthy region and a mean of 0.1568 and standard deviation of 0.0401 in the infarcted region. Fig. 4 shows the mean FA in both regions over one cardiac cycle. Separation of these tissue types is evident in both data representations.

Conclusion

A scalar index is proposed for characterization of three-dimensional myocardial strain tensor anisotropy. Results in a pig model show this measure is correlated with tissue viability. Classification and characterization of healthy and diseased myocardium is therefore possible using three-dimensional strain FA.

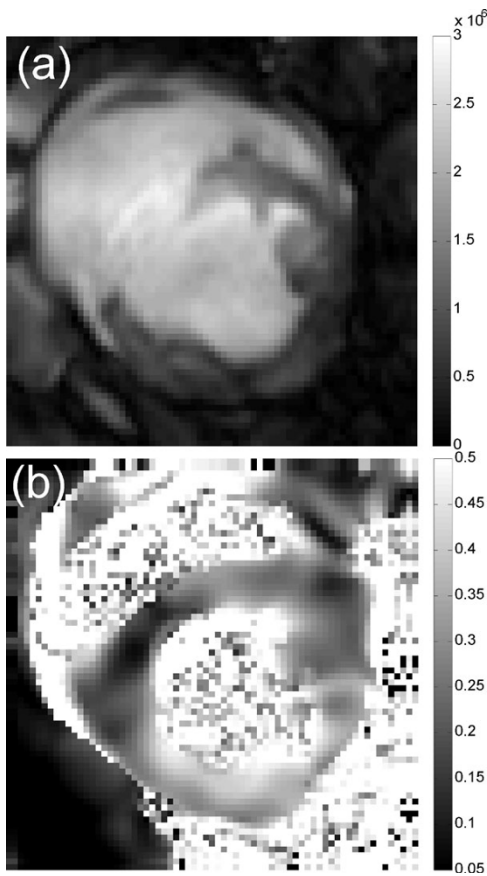


Figure 1
(a) Delayed enhancement and (b) fractional anisotropy map of 3D strain tensor during end-systole.

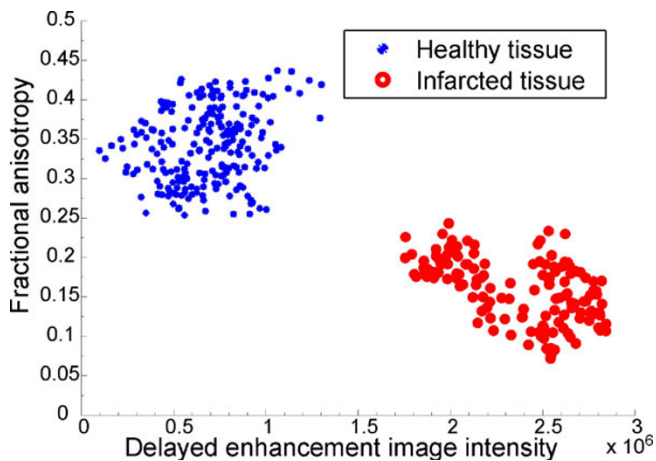


Figure 2
Plot delayed enhancement image intensity vs. end-systolic fractional anisotropy for health and infarcted regions of myocardium shown in Figure 3.

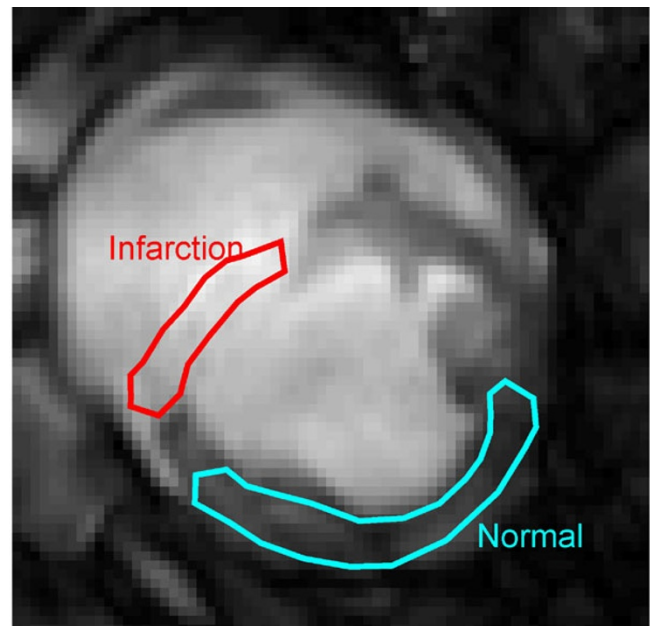


Figure 3
Delayed enhancement image at mid-diastole marked with infarcted and health tissue of the myocardium used for analysis.

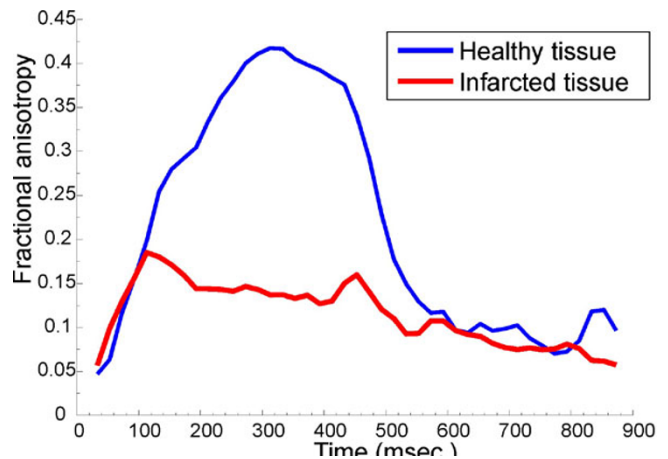


Figure 4
Average FA over one cardiac cycle for both tissue types in regions of myocardium shown in Figure 3.

References

1. Abd-Elmoniem , et al.: *Medical Image Analysis* 2009:778-786.
2. Basser , et al.: *J Magn Reson, B* 1996:209-219.
3. Abd-Elmoniem , et al.: *Magn Reson In Med* 2007:92-102.