

POSTER PRESENTATION

Open Access

Quantitative analysis of post-TAVI aortic regurgitation with cardiovascular magnetic resonance and the relationship to transthoracic echocardiography

Akhlaque Uddin^{1*}, Timothy Fairbairn¹, Christopher D Steadman², Bernhard A Herzog¹, Manish Motwani¹, Ananth Kidambi¹, Dominik Schloschan³, Daniel Blackman³, Gerry P McCann², Sven Plein¹, John P Greenwood¹

From 16th Annual SCMR Scientific Sessions
San Francisco, CA, USA. 31 January - 3 February 2013

Background

Transcatheter Aortic Valve Implantation (TAVI) is increasingly used to treat patients with severe aortic stenosis at high surgical risk. The severity of post-implantation valvular or paravalvular regurgitation has been shown to adversely affect patient outcome. The aim of the study was to assess the prevalence and severity of aortic regurgitation (AR) at 6 months post-TAVI using cardiovascular magnetic resonance (CMR).

Methods

Twenty five severe aortic stenosis patients underwent a 1.5T CMR (Intera, Philips Healthcare) scan at baseline and 6 months after CoreValve™ TAVI. LV function was assessed using cine imaging with a steady state free precession pulse sequence. The LV outflow tract was imaged in two planes and through-plane phase contrast velocity imaging was performed perpendicular to the aortic valve and transverse to the aorta at the sinotubular junction. Post-processing was performed using QMass 7.2 and QFlow 5.2 (Medis, Netherlands). AR severity was defined using regurgitant fraction (RF) as: none to mild <8%, mild to moderate 8 to 19%, moderate to severe 20 to 29% and severe >30% [1].

Transthoracic echocardiography (iE33, Philips Healthcare) was performed at baseline and 6 months follow-up. Aortic regurgitation was graded using a comprehensive

integrated approach following the recent Valve Academic Research Consortium (VARC) guidelines.

Results

Mean age was 80.6±6.6yrs, 44% were female, Logistic EuroSCORE 19.5±14.9 LV ejection fraction significantly improved post-TAVI (52.1±11.8% vs. 55.9±9.6%, $p < 0.0001$) and reduction in indexed end-systolic LV volume (46±18 ml/m² vs. 41±17 ml/m², $p = 0.02$). The end-diastolic volume (95±18 ml/m² vs. 91±20 ml/m², $p = ns$) and stroke volume (48±10 ml/m² vs. 50±10 ml/m², $p = ns$) did not change.

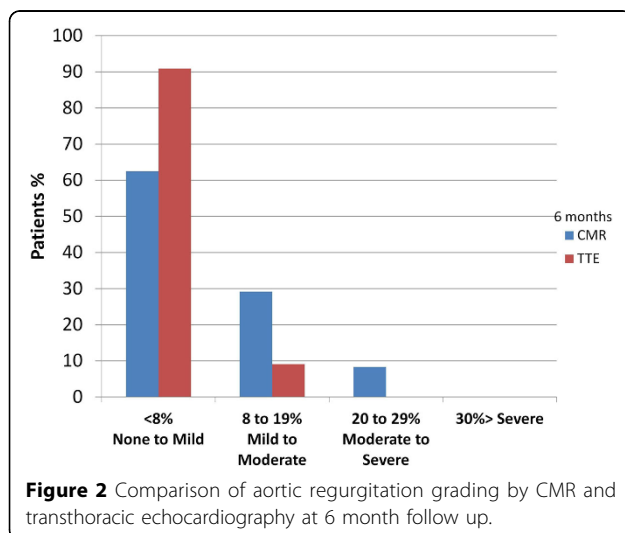
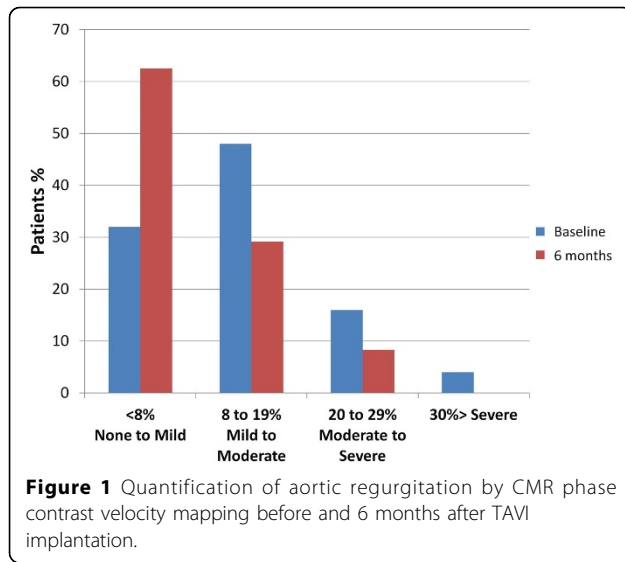
There was a significant reduction in aortic RF 6 months post-TAVI (median RF 12.4%, IQR 5.6 to 16.8% vs. 6.2% IQR 3.6 to 13.2%, $p = 0.034$) (Figure 1). There was no significant difference between the transthoracic echo grading and CMR grading of aortic regurgitation. (Chi-squared = 3.74 $p = 0.159$) (Figure 2).

Echocardiography showed there was also a statistically significant reductions in peak forward flow velocity (4.87 ±0.57 ms⁻¹ vs. 1.98±0.35 ms⁻¹ $p < 0.05$), peak pressure gradient (96.1±24.3 mmHg vs. 17±5.7 mmHg $p < 0.05$) and mean pressure gradient (54.8±15.9 mmHg vs. 8±3 mmHg $p < 0.05$) compared to baseline; the effective orifice area (EOA) was significantly larger compared to the baseline state (0.57±0.03 cm² vs. 1.63±0.3cm² $p < 0.05$).

Conclusions

There was an overall reduction in aortic regurgitant fraction post-TAVI even in the presence of pre-existing AR. CMR can be used in the TAVI population, pre- and post-procedure to quantify the degree of aortic regurgitation

¹Academic Unit of Cardiovascular Medicine, Multidisciplinary Cardiovascular Research Centre (MCRC) & Leeds Institute of Genetics, Health and Therapeutics, Leeds, UK
Full list of author information is available at the end of the article



Funding

SP is funded by a British Heart Foundation fellowship (FS/10/62/28409).

SP and JPG receive an educational research grant from Philips Healthcare.

Author details

¹Academic Unit of Cardiovascular Medicine, Multidisciplinary Cardiovascular Research Centre (MCRC) & Leeds Institute of Genetics, Health and Therapeutics, Leeds, UK. ²National Institute for Health Research (NIHR) Leicester Cardiovascular Biomedical Research Unit, University of Leicester, Leicester, UK. ³Department of Cardiology, Leeds Teaching Hospitals NHS trust, Leeds General Infirmary, Leeds, UK.

Published: 30 January 2013

Reference

1. Gabriel RS, Renapurkar R, Bolen MA, Verhaert D, Leiber M, Flamm SD, Griffin BP, Desai MY: **Comparison of severity of aortic regurgitation by cardiovascular magnetic resonance versus transthoracic echocardiography.** *Am J Cardiol* 2011, **108**(7):1014-20.

doi:10.1186/1532-429X-15-S1-P114

Cite this article as: Uddin *et al.*: Quantitative analysis of post-TAVI aortic regurgitation with cardiovascular magnetic resonance and the relationship to transthoracic echocardiography. *Journal of Cardiovascular Magnetic Resonance* 2013 **15**(Suppl 1):P114.

Submit your next manuscript to BioMed Central and take full advantage of:

- Convenient online submission
- Thorough peer review
- No space constraints or color figure charges
- Immediate publication on acceptance
- Inclusion in PubMed, CAS, Scopus and Google Scholar
- Research which is freely available for redistribution

Submit your manuscript at
www.biomedcentral.com/submit

