

Phase contrast 4D flow in bicuspid aortic valves in a porcine model

Matthias Grothoff^{1*}, Dr Christian Etz², Bernhard Preim³, Benjamin Köhler³, Matthias Gutberlet¹

From 18th Annual SCMR Scientific Sessions
Nice, France. 4-7 February 2015

Background

Bicuspid aortic valves (BAV) are associated with aneurysms of the ascending aorta (AAA). It is unclear whether these aneurysms are caused by tissue alterations of the aortic wall or by alterations of blood flow in the ascending aorta due to the bicuspid valve morphology. In this study we analyzed the phase contrast 4D flow characteristics in normal tricuspid aortic valves (TAV) in a porcine model and compared them to the 4D flow patterns after different types of surgical bicuspidalization.

Methods

Phase contrast 4D flow measurements of the thoracic aorta were performed in 3 mongrel swine (56 to 73 kg) using a spoiled gradient-echo based sequence prototype on a 3 Tesla MRI system (Verio, Siemens Healthcare, Erlangen, Germany) in supine position with a 16-channel cardiac phase-array coil. After the first MRI scan surgical bicuspidalization of the aortic valve was performed with a fusion of the right and left-coronary (R-

L) leaflet in swine 1 and fusion of the right and the non-coronary (R-N) leaflet in swine 2. In swine 3 a congenital BAV of the R-L type was found intraoperatively. After surgery swine 1 and 2 underwent a second 4D flow scan. The 4D scans were analyzed for helical and vortical flow in the entire thoracic aorta and for eccentric flow at the level of the sinotubular junction.

Results

Analysis of preoperative 4D flow characteristics in swine 1 and 2 revealed a predominantly laminar flow with high-velocity systolic streamlines parallel to the aortic wall and only discrete-right handed flow in the distal aortic arch and the descending aorta without helicity (Fig. 1). No vortices and no eccentric flow at the level of the sinotubular junction could be detected. Swine 3 (congenital BAV) demonstrated a marked right-handed helical flow in peak systole.

Postoperative analysis demonstrated substantial changes: In swine 1 (R-L) a right-handed helical flow was

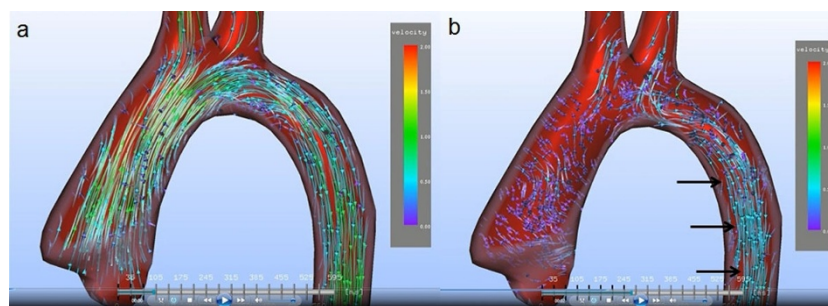


Figure 1 Preoperative streamline analysis of pig 1 with a normal tricuspid aortic valve in systole (a) and early diastole (b). In (a) laminar flow is shown in the ascending aorta, the aortic arch and the proximal descending aorta. No helical or vortical flow is present. In (b) laminar flow is still present in the proximal descending aorta (in black arrows).

¹Radiology, Leipzig Heart Center, Leipzig, Germany
Full list of author information is available at the end of the article

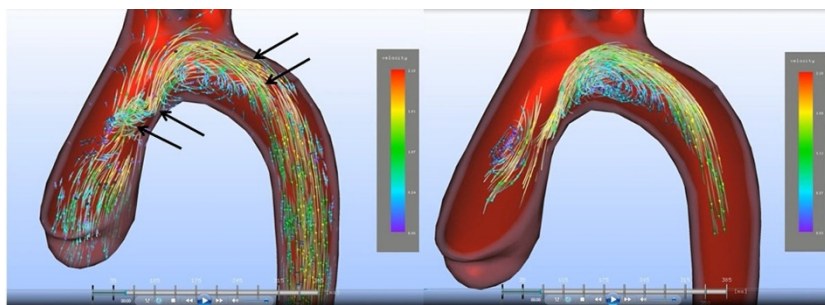


Figure 2 Postoperative streamline analysis of pig 1 after bicuspidalization with right-left aortic leaflet fusion. In (a) there is a right-handed helical flow in the ascending aorta and the distal aortic arch (arrows). In (b) vortices are extracted from the image data. A big vortex can be visualized in the aortic arch, a small vortex in the ascending aorta.

visible in the ascending aorta and the aortic arch with a corresponding eccentric flow with a jet towards the right-anterior quadrant at the level of the sinotubular junction. Extraction of vortices showed a pronounced vortex in the aortic arch and in the AA (Fig. 2). In swine 2 (R-N) an eccentric flow with a jet towards the left-posterior quadrant at the level of the sinotubular junction was visible and vortices could be detected in the AA.

Conclusions

We could show that bicuspidalization of the aortic valve results in substantial changes of blood flow in the AA depending on the type of leaflet fusion. This porcine model could be used to analyze the contribution of flow alterations in the development of AAA in BAV patients.

Funding

None.

Authors' details

¹Radiology, Leipzig Heart Center, Leipzig, Germany. ²Cardiac Surgery, Leipzig Heart Center, Leipzig, Germany. ³Computer Science, University Magdeburg, Magdeburg, Germany.

Published: 3 February 2015

doi:10.1186/1532-429X-17-S1-P416

Cite this article as: Grothoff *et al.*: Phase contrast 4D flow in bicuspid aortic valves in a porcine model. *Journal of Cardiovascular Magnetic Resonance* 2015 **17**(Suppl 1):P416.

Submit your next manuscript to BioMed Central and take full advantage of:

- Convenient online submission
- Thorough peer review
- No space constraints or color figure charges
- Immediate publication on acceptance
- Inclusion in PubMed, CAS, Scopus and Google Scholar
- Research which is freely available for redistribution

Submit your manuscript at
www.biomedcentral.com/submit

 **BioMed Central**