

POSTER PRESENTATION

Open Access

# A qualitative and quantitative assessment of cardiac cine Phase contrast MRI: comparison of image quality between 2D and 3D acquisition

Munemura Suzuki<sup>1,2\*</sup>, Takahiko Nakazono<sup>1</sup>, Ken Yamaguchi<sup>1</sup>, Kiyoshi Dogomori<sup>1</sup>, Yoshiaki Komori<sup>4</sup>, Norihiko Kotooka<sup>3</sup>, Koichi Node<sup>3</sup>, Hiroyuki Irie<sup>1</sup>

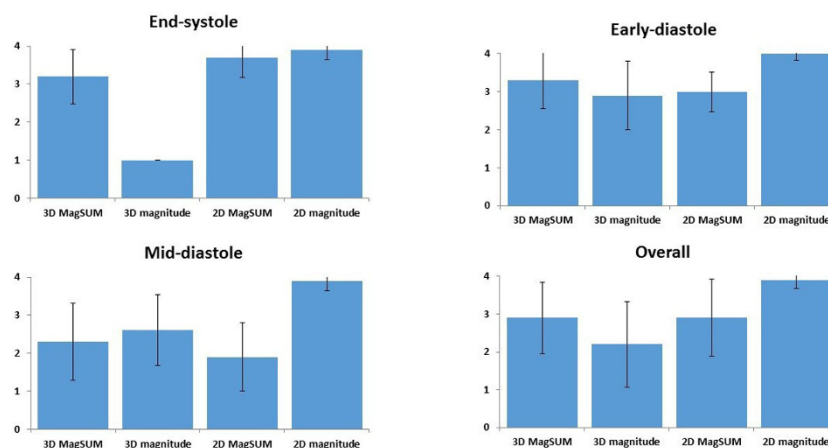
From 18th Annual SCMR Scientific Sessions  
Nice, France. 4-7 February 2015

## Background

3D and gapless multi-slice 2D cine Phase contrast (PC) MRI enables the visualization and analysis of 4D (3D + time) intracardiac flow. However, the image quality which affects the accuracy of segmentation of left ventricle (LV) has not been discussed. In this study, we compared the magnitude image and the source image of PC MR angiography (MagSUM) derived from both 2D and 3D PC MRI. For the qualitative analysis, we assessed the image quality for the delineation of endocardial border. And we measured LV volume and compared with standard cine MRI for the quantitative analysis.

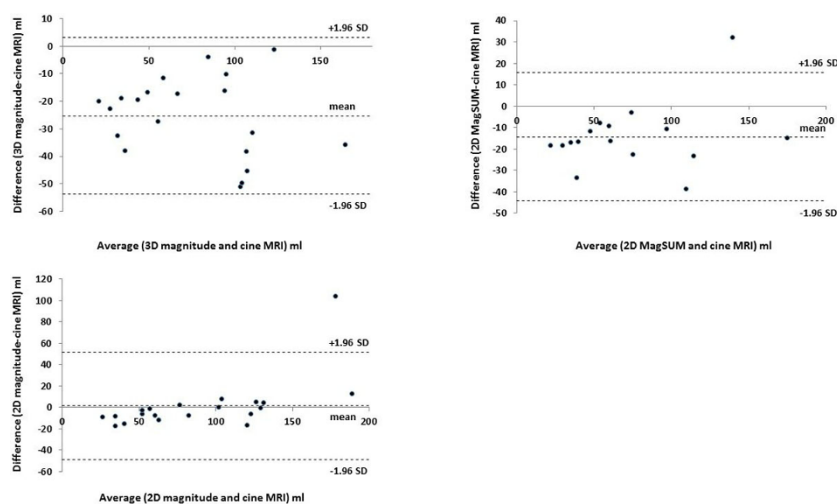
## Methods

Ten healthy volunteer (all male, median age: 24 years) underwent 2D and 3D prospectively ECG-gated PC MRI with respiratory navigation on 3T MRI (Trio a Tim, Siemens AG Healthcare Sector, Erlangen, Germany). The short axial plane was employed to cover left ventricle. The common parameters for PC MRI were: VENC = 150 cm/sec, segmentation factor = 2 to 3, reconstruction phase = 12 to 14 according to R-R interval. The acquisition voxel of 2D and 3D PC MRI were reconstructed into 2.1x2.1x5 mm and 2.1x2.1x2.1 mm, respectively. Standard 2D retrospectively ECG-gated cine MRI was reconstructed to 2.1x1.8x8 mm. Two readers discussed and determined the



**Figure 1** Quantitative analysis of image quality (4-point scale) for delineation of endocardial border (MagSUM: the source image of phase contrast MRI).

<sup>1</sup>Radiology, Saga University Hospital, Saga, Japan  
Full list of author information is available at the end of the article



**Figure 2** Bland-Altman Plot for left ventricular volume measured by phase contrast MRI and standard cine MRI.

image quality for one short axial image (mid-ventricle level), and two reconstructed images (vertical and horizontal long axial image) of end-systolic, early- and mid-diastolic phase using 4 point scale (1 = poor, 2 = fair, 3 = good, 4 = excellent). One blinded reader manually measured the area of LV chamber and multiplied by the slice thickness and added together to obtain the end-systolic and mid-diastolic LV volume using PC MRI. Another blinded reader also measured cine MRI as reference standard.  $P < 0.05$  was regarded as significant.

## Results

The magnitude image of 2D PC MRI provided the best image quality. We could not recognize the endocardial border in 3D magnitude image at end-systolic phase in all case and excluded from quantitative analysis (Figure 1). Four 2D MagSUM images were also excluded because of significant artifacts. Strong correlation of LV volume were seen between PC MRI and cine MRI (3D MagSUM, 2D MagSUM:  $r = 0.94$  and 2D magnitude:  $r = 0.91$ ) although the 2D and 3D MagSUM images systematically underestimated (Figure 2).

## Conclusions

The magnitude image of 2D PC MRI seems to provide accurate segmentation of LV. We have to pay attention when using MagSUM image of 2D and 3D PC MRI for LV segmentation.

## Funding

N/A.

## Authors' details

<sup>1</sup>Radiology, Saga University Hospital, Saga, Japan. <sup>2</sup>Suzuki Medicalimaging Labo, Kagoshima, Japan. <sup>3</sup>Cardiology, Saga University Hospital, Saga, Japan. <sup>4</sup>Research & Collaboration Department, Siemens Japan K.K., Tokyo, Japan.

Published: 3 February 2015

doi:10.1186/1532-429X-17-S1-P54

**Cite this article as:** Suzuki *et al.*: A qualitative and quantitative assessment of cardiac cine Phase contrast MRI: comparison of image quality between 2D and 3D acquisition. *Journal of Cardiovascular Magnetic Resonance* 2015 **17**(Suppl 1):P54.

**Submit your next manuscript to BioMed Central and take full advantage of:**

- Convenient online submission
- Thorough peer review
- No space constraints or color figure charges
- Immediate publication on acceptance
- Inclusion in PubMed, CAS, Scopus and Google Scholar
- Research which is freely available for redistribution

Submit your manuscript at  
www.biomedcentral.com/submit

