

POSTER PRESENTATION

Open Access

Post-contrast T1-mapping provides a novel approach to optimal myocardial nulling for late gadolinium enhancement imaging: a quantitative prescription for the correct TI without the guesswork

Vanessa M Ferreira^{*}, Alexander Liu, Claudia Marini, Anne Davis, Jane M Francis, Stefan Neubauer, Stefan K Piechnik

From 19th Annual SCMR Scientific Sessions
Los Angeles, CA, USA. 27-30 January 2016

Background

Late gadolinium enhancement (LGE) is a well-established technique that generates excellent contrast between normal and pathologic myocardium. Selecting the correct inversion time (TI) for nulling normal myocardium is essential for good quality images and accurate diagnosis. The Look-Locker (LL) TI scout is commonly used for TI estimation but is subjective and requires a long breath-hold (20 heartbeats). T1-mapping is a quantitative method that can provide a direct numeric TI prescription in a shorter breath-hold but has not been tested in practice.

Methods

CMR: 39 subjects (19 men, 51 ± 16 yrs) with a variety of cardiac conditions underwent CMR at 1.5T (Siemens Avanto MR system; Syngo VB17A). All received intravenous gadolinium contrast (Gadoterate meglumine, Dotarem; 0.10 mmol/kg). Imaging included the LL TI scout followed immediately by post-contrast T1-mapping (ShMOLLI; WIP561; 9 heartbeats) at a mid-ventricular short-axis slice, and LGE (PSIR) imaging using conventional TI selection based on visual assessment of the TI scout according to radiographer experience.

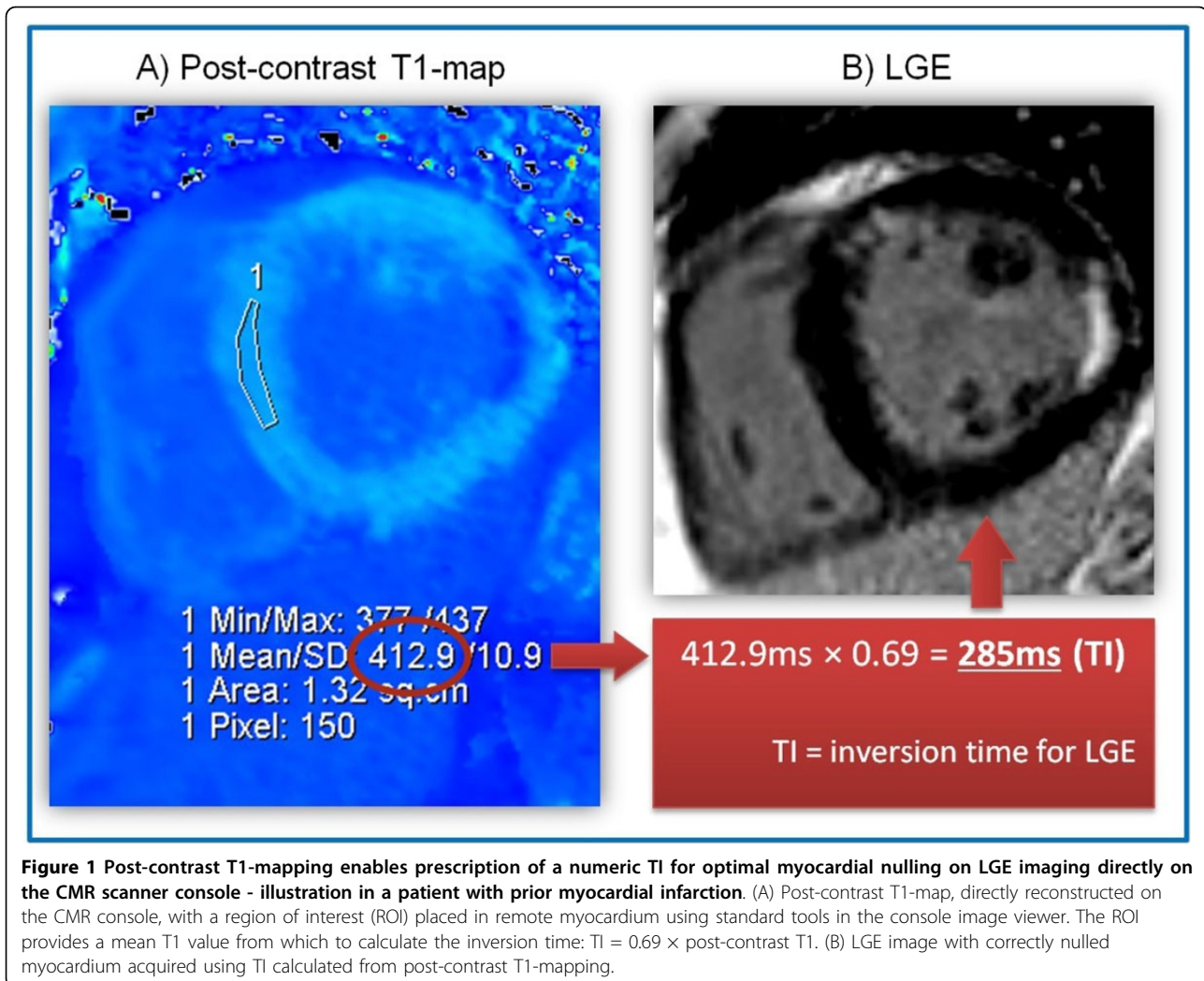
Image processing: matching regions of interest (ROIs) were prescribed on LL TI scout, post-contrast T1-maps and LGE images in an area of the LV without obvious

abnormality. LL TI was calculated by linear interpolation of sign reconstructed from the 5-6 lowest SI measurements, while T1-map TI was calculated as $TI = 0.69 \times T1$ from post-contrast T1-maps. We also measured the average SI of the ROI on LGE images to assess for adequate nulling (SI=0) of the myocardium.

Results

There was excellent correlation ($r^2=0.77$, $p < 0.01$) between the TI calculated from LL TI scouts and post-contrast T1-maps. The LL TI was 37 ms shorter than T1map TI, consistent with the speed of T1 recovery between measurements (~15 ms/min; *Messroghli et al, MRM 2007*), combined with T1 correction for this T1-mapping sequence (*Piechnik et al, JCMR 2015*). In 18% (7/39) of the cases, the operator did not prescribe the correct TI, predominantly when the correct TI is short but the operator overestimated by assuming a starting TI of 300 ms typical for PSIR LGE imaging. Deviation of the prescribed TI from the calculated TI was correlated to suboptimal nulling of the myocardium, whether calculation of the TI was performed using ROIs on LL TI scouts ($r^2=0.34$) or post-contrast T1-maps ($r^2=0.42$). Figure 1 shows an example of using T1-mapping to prescribe a numerical TI, directly on the CMR console, for optimal myocardial nulling on LGE.

Division of Cardiovascular Medicine, Radcliffe Department of Medicine, University of Oxford, John Radcliffe Hospital, Oxford, UK



Conclusions

Post-contrast T1-mapping is an easy way to provide a direct numeric TI for optimal myocardial nulling in a single short breath-hold, reducing operator error and improving robustness for LGE imaging.

Published: 27 January 2016

doi:10.1186/1532-429X-18-S1-P22

Cite this article as: Ferreira et al.: Post-contrast T1-mapping provides a novel approach to optimal myocardial nulling for late gadolinium enhancement imaging: a quantitative prescription for the correct TI without the guesswork. *Journal of Cardiovascular Magnetic Resonance* 2016 **18**(Suppl 1):P22.

Submit your next manuscript to BioMed Central and take full advantage of:

- Convenient online submission
- Thorough peer review
- No space constraints or color figure charges
- Immediate publication on acceptance
- Inclusion in PubMed, CAS, Scopus and Google Scholar
- Research which is freely available for redistribution

Submit your manuscript at
www.biomedcentral.com/submit

 BioMed Central