



RESEARCH

Open Access

Right coronary wall cmr in the older asymptomatic advance cohort: positive remodeling and associations with type 2 diabetes and coronary calcium

Masahiro Terashima¹, Patricia K Nguyen¹, Geoffrey D Rubin², Craig H Meyer³, Ann Shimakawa⁴, Dwight G Nishimura⁵, Shoichi Ehara¹, Carlos Iribarren⁶, Brian K Courtney¹, Alan S Go^{6,7}, Mark A Hlatky^{1,8}, Stephen P Fortmann⁹, Michael V McConnell^{1,5*}

Abstract

Background: Coronary wall cardiovascular magnetic resonance (CMR) is a promising noninvasive approach to assess subclinical atherosclerosis, but data are limited in subjects over 60 years old, who are at increased risk. The purpose of the study was to evaluate coronary wall CMR in an asymptomatic older cohort.

Results: Cross-sectional images of the proximal right coronary artery (RCA) were acquired using spiral black-blood coronary CMR (0.7 mm resolution) in 223 older, community-based patients without a history of cardiovascular disease (age 60-72 years old, 38% female). Coronary measurements (total vessel area, lumen area, wall area, and wall thickness) had small intra- and inter-observer variabilities ($r = 0.93-0.99$, all $p < 0.0001$), though one-third of these older subjects had suboptimal image quality. Increased coronary wall thickness correlated with increased coronary vessel area ($p < 0.0001$), consistent with positive remodeling. On multivariate analysis, type 2 diabetes was the only risk factor associated with increased coronary wall area and thickness ($p = 0.03$ and $p = 0.007$, respectively). Coronary wall CMR measures were also associated with coronary calcification ($p = 0.01-0.03$).

Conclusions: Right coronary wall CMR in asymptomatic older subjects showed increased coronary atherosclerosis in subjects with type 2 diabetes as well as coronary calcification. Coronary wall CMR may contribute to the noninvasive assessment of subclinical coronary atherosclerosis in older, at-risk patient groups.

Introduction

Noninvasive imaging techniques to assess subclinical coronary atherosclerosis have the potential to identify patients at higher risk for future coronary events and guide lifestyle modifications and pharmacological therapy to maximize cardiovascular risk reduction. Over the last decade, significant progress has been made in the development of coronary magnetic resonance angiography using a variety of techniques [1-5]. However, the assessment of coronary artery luminal narrowing has limited value for the detection of subclinical coronary

atherosclerosis because the coronary artery lumen size is often preserved by positive arterial remodeling[6]. Therefore, direct noninvasive imaging of the coronary artery wall is an important target for cardiovascular imaging.

While coronary wall imaging by cardiovascular magnetic resonance (CMR) is challenging due to the small size of coronary arteries and cardiac/respiratory motion, it has been successfully applied in patients using breath-hold[7-9] or respiratory gating (i.e., free-breathing) techniques[10-14]. Using these techniques, significant increases in coronary wall area and wall thickness have been found in patients with documented coronary artery disease[10,12] and in those with type 1 diabetes mellitus plus nephropathy [13]. The MESA study more recently

* Correspondence: mcconnell@stanford.edu

¹Division of Cardiovascular Medicine, Stanford University School of Medicine, Stanford, CA, USA

Full list of author information is available at the end of the article

showed positive arterial remodeling by coronary wall CMR in 179 asymptomatic participants[14]. There are limited data on evaluating subclinical atherosclerosis in older patient groups, who are at increased risk for coronary events.

We have investigated clinical, imaging, and genetic abnormalities in an at-risk (i.e., older) community-based patient cohort - the Atherosclerotic Disease, Vascular Function, and Genetic Epidemiology (ADVANCE) study [15,16]. Here we report on coronary wall CMR in this older, asymptomatic cohort to assess image quality, measurement variability, remodeling, and risk factor associations.

Methods

Study Patients

This was an CMR sub-study of 223 participants from the ADVANCE study of 1023 older subjects (age 60 to 72 years, 34% women) with details on the patient cohort published previously[5,16]. Briefly, subjects without a known history of cardiovascular disease or other major comorbidities were randomly selected from the membership of Kaiser Permanente of Northern California. All subjects were studied through the Stanford Prevention Research Center. Coronary risk factors were measured using standardized protocols[17]. Diabetes mellitus was defined as self-report of physician-diagnosed diabetes, use of diabetes medication, or fasting blood glucose ≥ 126 mg/dl at the study visit[18]. Hypertension was defined as use of antihypertensive medication or blood pressure $\geq 140/90$ mmHg at study visit. Multi-detector row spiral computed tomography (CT) was used to quantify coronary artery calcification (CAC) by the Agatston score, as previously reported[16,19].

Written informed consent was obtained from all participants. The study protocol was approved by the Institutional Review Boards of Stanford University and the Kaiser Foundation Research Institute.

Coronary Wall Imaging by CMR

A 1.5T Signa MR scanner (GE Healthcare, Waukesha, WI) was used, equipped with high-performance gradients (40 mT/m, 150 mT/m/ms) and a commercial 4-channel cardiac phased-array surface coil (GE Healthcare, Waukesha, WI). A real-time interactive MR system (iDrive, GE Healthcare, Waukesha, WI) was used for coronary localization. For determination of the most quiescent period of the right coronary artery (RCA) within the cardiac cycle, a 2 D cine scan was performed in the 4-chamber view. High-resolution bright-blood coronary MRA, as previously reported[1,20], was performed to obtain in-plane views of the right coronary artery (RCA). Then, 3 cross-sectional coronary wall images of a linear portion of the proximal-to-mid RCA

were acquired with 3 separate breathholds using a spiral black-blood coronary CMR sequence, with cardiac gating and acquisition during the previously identified patient-specific quiescent period. This sequence used an interleaved spiral k-space trajectory technique incorporating 1) double-inversion preparation (DIR) to null the blood signal, 2) spectral-spatial excitation for water-selective imaging, and 3) spiral readout (field of view = 22 cm, in-plane spatial resolution = 0.7 mm, slice thickness = 5 mm, slice gap = 0 mm, DIR thickness = 10 mm, TR = 1 heart beat, TE = 2.5 ms, TI = 280-350 ms adjusted for heart rate, flip angle = 90°, 18 interleaves, temporal acquisition window = 34 ms, scan time typically 20 sec per breathhold)[9].

MR Image Analysis

Using the 3 cross-sectional RCA wall images, the image where the RCA wall exhibited the best image quality and the most circular cross-section was identified. Before quantitative analysis, image quality was rated on the MR images using a 4-point scale (4 = good, 3 = fair, 2 = poor, and 1 = very poor) based on signal-to-noise ratio (SNR), vessel border sharpness, and artifacts[21]. An image quality of 3 or above was considered adequate for quantitative analysis (Figure 1). These images were all pooled and then analyzed, blinded to patient information. Cross-sectional measurements of the total vessel area (VA) and lumen area (LA) of the RCA were performed manually using a custom-designed CMR analysis software after the images were magnified two-fold[5,22]. The coronary wall area (WA) was calculated as $WA = VA - LA$. The mean wall thickness (WT) was calculated assuming a circular vessel shape: $WT = (\sqrt{VA} - \sqrt{LA}) / \sqrt{\pi}$. All MR images were re-measured to assess intra- and inter-observer variability.

Statistical Analysis

Continuous variables are expressed as means with standard deviations or medians with inter-quartile ranges. Differences between two groups for continuous variables

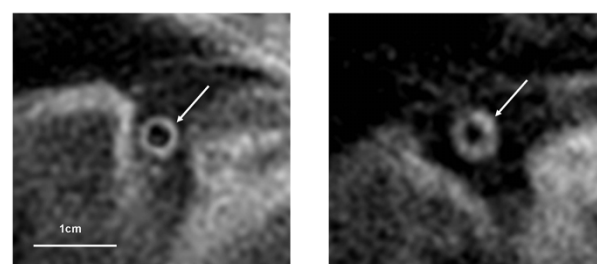


Figure 1 Representative images of spiral black-blood coronary wall CMR (arrows) showing patients at the low and high end for mean coronary wall thickness (left - 1.27 mm, right - 2.06 mm).

were compared using Student's t-test or the Mann-Whitney U test. Differences in categorical variables among groups of interest were assessed using chi-squared tests. Measurements variability was assessed by both linear regression analysis and Bland-Altman analysis. Multivariate regression analysis was performed to identify predictors for increased coronary wall area and wall thickness. Traditional coronary risk factors, such as age, gender, body mass index (BMI), diabetes mellitus, hypertension, total/HDL cholesterol ratio, and current smoking were included in the final multivariate regression model. Spearman rank correlation analysis was performed for the relationship between CAC (log [CAC+1]) and coronary vessel area, lumen area, wall area, and wall thickness. A two-sided p value < 0.05 was considered statistically significant and all analyses were performed using StatView statistical software (SAS institute, Cary, North Carolina).

Results

Subject Characteristics

The mean age was 66 ± 3 years, 33% were women, and 37% were non-Caucasian (Table 1). Hypertension was common (56%), while 17% had type 2 diabetes mellitus and <8% were cigarette smokers. CAC > 0 was present in 78% (n = 173) of subjects.

Coronary Wall Image Quality, Measurement Variability, Arterial Remodeling

Image quality of coronary wall CMR was >2 (fair or good) in 67% of subjects, leaving a total of 150 subjects for quantitative analysis. Bland-Altman analysis showed small differences for the intra- and inter-observer measurements of VA, WA, LA, and WT (Figure 2). The intra- and inter-observer variabilities were also low by linear regression analysis, with correlation coefficients of 0.93-0.99 (all p < 0.0001).

Mean coronary measurements by CMR were as follows: VA = 32.1 ± 8.2 mm², WA = 22.8 ± 5.9 mm², LA = 9.3 ± 3.4 mm², and WT = 1.48 ± 0.25 mm. VA increased with

increasing WT (r = 0.66, p < 0.0001, Figure 3), while LA remained constant (r = 0.05, p = 0.6). The increase in VA, but not LA, with an increase in WT is consistent with positive arterial remodeling [10,14].

Subclinical Coronary Atherosclerosis by CMR and Coronary Risk Factors

We compared coronary CMR measures to the clinical risk factors listed in Table 1. By univariate analysis, increased coronary WA and WT were associated with male gender (WA: 23.6 ± 5.9 vs. 21.7 ± 6.0 mm², p = 0.045; WT: 1.51 ± 0.24 vs. 1.43 ± 0.26 mm, p = 0.046), diabetes (WA: 25.5 ± 6.2 vs. 22.4 ± 5.8 mm², p = 0.04; WT: 1.61 ± 0.25 vs. 1.46 ± 0.24 mm, p = 0.008), and BMI (WA: r = 0.16, p = 0.046; WT: r = 0.2, p = 0.01). Total/HDL cholesterol ratio was associated with WT (r = 0.22, p = 0.008), but not WA. There were no significant associations between these risk factors and either VA or LA.

In multivariate analysis (Table 2), gender and BMI were no longer significant. Total/HDL cholesterol ratio remained independently associated with WT (p = 0.03), but not WA. Only diabetes was independently associated with both coronary WA (p = 0.04) and WT (p = 0.007). Differences in coronary measures between diabetics and non-diabetics are shown in Figure 4.

Coronary Wall Measurements by CMR and Coronary Artery Calcification

By Spearman rank correlation analysis, there was a significant correlation of CAC with coronary VA (p = 0.01), WA (p = 0.01), and WT (p = 0.03) (r = 0.18~0.21), but not coronary LA (p = 0.07). All coronary measurements were significantly increased in patients with any calcification of the RCA (p < 0.005, Figure 5).

Discussion

We investigated coronary wall CMR in a cohort of asymptomatic older subjects, which to our knowledge is the largest group studied by coronary wall CMR to date and the first to focus on patients > 60 years old. The main findings were: 1) adequate coronary wall image quality was achieved in two thirds of the subjects and measurements had very good intra- and inter-observer variability, 2) coronary wall measurements were consistent with positive arterial remodeling, 3) coronary atherosclerosis by CMR was increased in subjects with type 2 diabetes and also 4) with increasing coronary calcification.

While coronary wall image quality and measurement variability have been reported in prior smaller studies, our study extends these findings to a large older community-based cohort where image quality can be challenging. This study confirms the positive arterial

Table 1 Clinical Characteristics of Study Subjects (n = 223)

Characteristic	
Age (years)	66.0 ± 2.7
Gender (men/women)	149/74
Body mass index (kg/m ²)	27.0 ± 4.3
Diabetes mellitus (n, %)	38 (17)
Hypertension (n, %)	124 (56)
Total/HDL cholesterol (mg/dL)	3.7 ± 1.0
Current smoker (n, %)	17 (7.6)

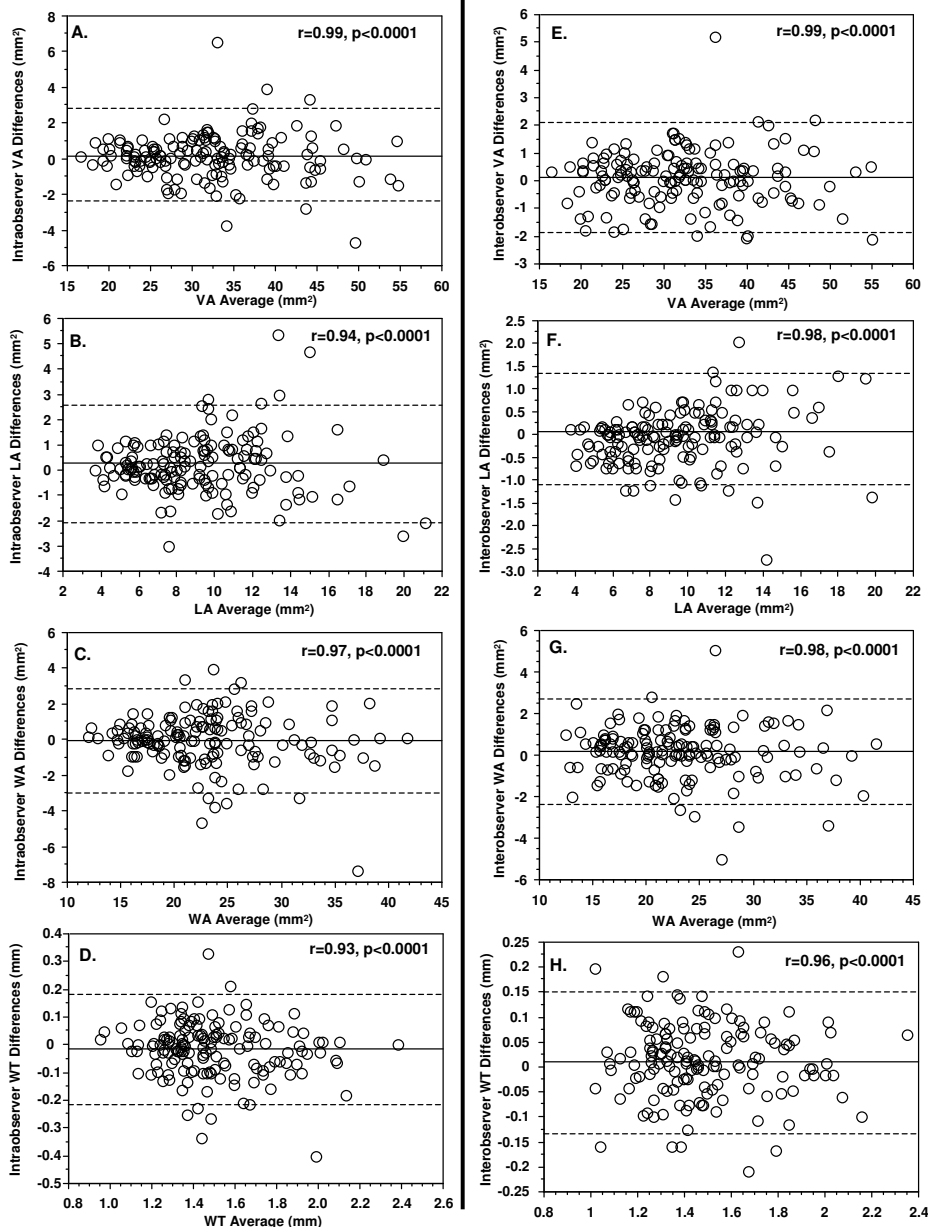


Figure 2 Bland-Altman plots of intra-observer (left panels) and inter-observer (right panels) differences in coronary CMR measurements. The solid lines are the mean differences and the dashed lines are 2 standard deviations (SD) from the mean difference. The linear regression analyses are also provided, with correlation coefficient and p value for each comparison.

remodeling and association with coronary calcium reported in the MESA study, but now also in a large cohort of subjects over 60 years old. The association with type 2 diabetes is novel.

Coronary Wall Imaging by CMR

Coronary wall CMR can be performed by breath-held and free breathing methods. To date, it has been shown to be reproducible in healthy volunteers[23,24] and to detect increased wall thickness in selected patients with

known coronary artery disease, type 1 diabetes complicated by diabetic nephropathy, and asymptomatic individuals from the MESA study[10,12-14,25].

In our study, the breath-held spiral black-blood coronary CMR sequence provided adequate image quality in 67% of subjects (age 60-72 years). This was somewhat lower than the 74% of coronary locations visualized that had adequate image quality in the MESA study (where the age ranged from 45 to 84 years[25]). There are a number of factors that may contribute to inadequate

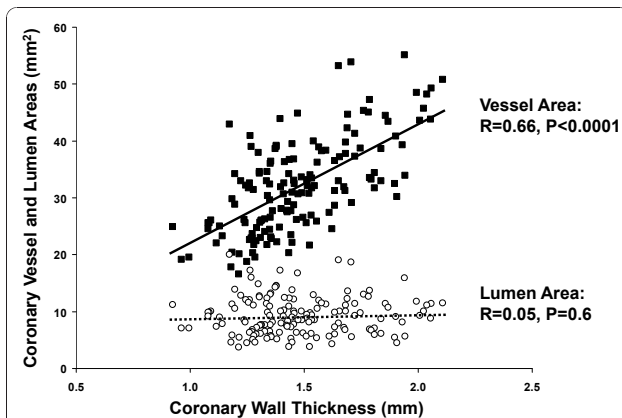


Figure 3 Coronary wall thickness compared to both vessel area (solid squares, solid line) and lumen area (open circles, dashed line) by linear regression, showing significant positive correlation for vessel area but no significant change in lumen area, consistent with positive remodeling.

image quality of coronary wall CMR, including suboptimal breath-holding, cardiac and respiratory motion artifacts, and limited signal-to-noise ratio (SNR). The short spiral readouts of this breath-held sequence limit SNR, which is why this study focused on the more anterior right coronary artery, as in most prior studies[9-13]. Increased BMI also likely contributed to reduced SNR, as obese patients (BMI ≥ 30 , accounting for 24% of cohort) were less likely to have adequate image quality (39.2% vs. 81.7% for BMI < 30). Notably, patients with CAC ≥ 400 were also less likely to have adequate MR image quality (52.5% vs. 70.5% for CAC < 400), suggesting that severe calcification (with low MR signal) limits coronary wall visualization. A higher proportion of our older cohort (78%) had evidence of coronary calcification compared to the MESA study (46%)[14].

Importantly, in those subjects with adequate image quality, quantitative measures had very good intra- and

Table 2 Multivariate Regression Analysis of Coronary Risk Factors and Coronary Wall CMR

Variable	Coronary VA ($p = 0.038$)			Coronary WT ($p = 0.0009$)		
	β value	SE	P Value	β value	SE	P Value
Age (years)	-0.024	0.176	0.981	0.022	0.007	0.783
Gender (men/women)	0.099	1.033	0.239	0.101	0.042	0.216
Body mass index (kg/m ²)	0.132	0.141	0.123	0.16	0.006	0.054
Diabetes mellitus (%)	0.177	1.402	0.037	0.223	0.057	0.007
Hypertension (%)	0.019	1.037	0.829	0.015	0.042	0.857
Total/HDL cholesterol (mg/dL)	0.105	0.49	0.226	0.189	0.020	0.025
Current smoker, n (%)	0.132	2.037	0.112	0.144	0.082	0.073

β : standardized regression coefficients. SE: standard error.

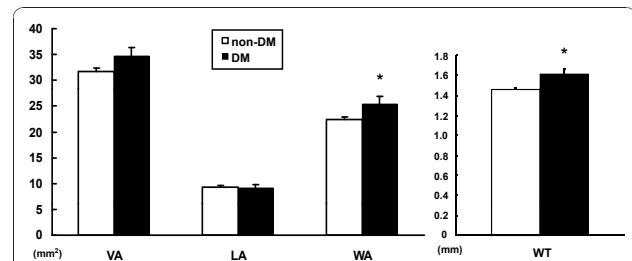


Figure 4 Coronary wall CMR measurements between non-diabetic (n = 128) and diabetic (n = 22) subjects. Both coronary wall area and wall thickness were significantly associated with diabetes mellitus (DM) by multivariate analysis. [* p < 0.05].

inter-observer agreement, which had only been shown previously in healthy volunteers[23,24]. Several approaches are likely needed in combination to improve image quality and SNR in order to make this a more robust and reliable technique. These include optimized multi-element surface coils, 3 D acquisition[10,23], free-breathing methods to allow longer acquisitions[26], radial *k*-space sampling[27], and higher magnetic field strength, such as 3T[28-31].

Positive Arterial Remodeling

The compensatory enlargement of artery size with increased atherosclerosis to maintain lumen size has been termed positive arterial remodeling. Our finding of increased coronary vessel area and preserved lumen area with increased coronary wall thickness confirms, in an older population, the prior reports of positive remodeling by coronary wall CMR[10,14]. Importantly, while male gender and BMI can affect vessel size, these were not associated with increased wall thickness on multivariate analysis. This identification of positive remodeling is potentially valuable clinically, as it has been associated with an increased risk of plaque rupture by pathology[8].

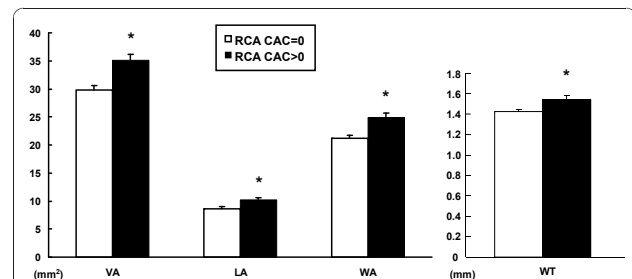


Figure 5 Coronary wall CMR measurements and RCA calcification. All coronary measurements were significantly greater in patients with positive RCA calcification (RCA CAC > 0, n = 84) compared to those without (RCA CAC = 0, n = 66). [* p < 0.005].

Diabetes and Subclinical Coronary Atherosclerosis

Among coronary risk factors, type 2 diabetes was the strongest predictor by multivariate analysis of increased coronary wall area and wall thickness by CMR in the present study. These results are consistent with autopsy and CT studies that have documented a higher prevalence of coronary atherosclerosis among patients with diabetes, even in the absence of symptoms or clinical evidence of coronary artery disease[32-34]. CMR of the RCA wall has been applied previously to a subset of 61 patients from a cohort of asymptomatic type 1 diabetics, with wall thickness found to be greater in patients who also had nephropathy[13]. In the MESA study, HDL and smoking history were associated with increased coronary wall thickness on univariate analysis, but no multivariate analysis data were provided[25]. The number of diabetics reported in MESA (n = 4) was likely too small for analysis of this association. Given the increasing incidence of type 2 diabetes, data on the prognostic utility of coronary wall CMR to identify diabetic patients at increased risk of progression to clinical coronary heart disease would clearly be valuable.

Coronary Wall CMR and Coronary Artery Calcification

CAC measured by CT has been the most widely used direct noninvasive measure of coronary atherosclerosis [35] and is associated with the extent of coronary atherosclerosis by pathology and clinical events[33,36]. Black-blood CMR can assess coronary wall thickness, but does so over a more limited region. Thus, CAC by CT and coronary wall thickness by CMR provide different measures of coronary atherosclerosis. We found a significant association of RCA coronary wall thickness with both total CAC and CAC of the RCA, similar to the MESA study[14]. Further studies comparing coronary CMR to CAC, as well as CT angiography, are clearly needed.

Study Limitations

There is a growing literature of coronary wall CMR studies, but limited validation with intravascular ultrasound, which cannot be justified in asymptomatic subjects. We imaged only a single region of the RCA, as in most prior studies, as the RCA is closer to the chest wall providing higher SNR and good reproducibility [10,23]. Atherosclerosis is a systemic disease that can cause a diffuse increase in coronary wall thickness, but more comprehensive imaging to also detect and characterize focal lesions would be desirable. The MESA study did include selected left main and left anterior descending artery locations, but ideally whole-heart coronary wall CMR methods are needed. Finally, the ultimate value of coronary wall CMR will be in predicting clinical events and guiding therapy.

Conclusions

Noninvasive right coronary wall CMR was successfully performed in a community-based cohort of older subjects, demonstrating positive arterial remodeling and association with type 2 diabetes and coronary artery calcification. Coronary wall CMR warrants further study in the detection of subclinical coronary atherosclerosis and prediction of clinical cardiovascular events.

Acknowledgements

We thank the staff at the Kaiser Permanente of Northern California Division of Research and the Stanford Prevention Research Center for their assistance in patient recruitment and evaluation. This study was supported by the Donald W. Reynolds Foundation (Las Vegas, NV), National Heart, Lung, and Blood Institute, R01-HL39297 (Bethesda, MD) and GE Healthcare (Waukesha, WI). The funding bodies did not influence any of the following: study design; collection, analysis, and interpretation of data; writing of the manuscript; and the decision to submit the manuscript for publication.

Author details

¹Division of Cardiovascular Medicine, Stanford University School of Medicine, Stanford, CA, USA. ²Department of Radiology, Stanford University School of Medicine, Stanford, CA, USA. ³Department of Biomedical Engineering, University of Virginia, Charlottesville, VA, USA. ⁴Applied Science Laboratory-West, GE Healthcare, Menlo Park, CA, USA. ⁵Magnetic Resonance Systems Research Laboratory, Department of Electrical Engineering, Stanford University School of Medicine, Stanford, CA, USA. ⁶Division of Research, Kaiser Permanente of Northern California, Oakland, CA, USA. ⁷Departments of Epidemiology, Biostatistics, and Medicine, University of California, San Francisco, San Francisco, CA, USA. ⁸Department of Health Research and Policy, Stanford University School of Medicine, Stanford, CA, USA. ⁹Stanford Prevention Research Center, Stanford University School of Medicine, Stanford, CA, USA.

Authors' contributions

MT performed CMR studies, data analysis, and drafted the manuscript. PKN performed CMR studies and data analysis. GDR participated in the study design and supervised the coronary CT exams and data analysis. CHM, AS, and DGN helped develop and implement the CMR methods. SE contributed to the data analysis. BC contributed to the CMR image analysis methods. CI, ASG, MAH, and SPF participated in the study design and contributed to data analysis methods. MVM participated in the study design, patient studies, and data analysis. All authors have participated in critical review of the manuscript and have read and approved the final version.

Competing interests

MVM and DGN receive research support from GE Healthcare. MVM has been an advisor for Philips Healthcare and Kowa, Inc. MT has received honoraria from Philips Healthcare. GDR has been an advisor for TeraRecon, Inc. and Siemens Medical Solutions. AS is an employee of GE Healthcare.

Received: 18 May 2010 Accepted: 30 December 2010

Published: 30 December 2010

References

1. Yang PC, Meyer CH, Terashima M, Kaji S, McConnell MV, Macovski A, Pauly JM, Nishimura DG, Hu BS: **Spiral magnetic resonance coronary angiography with rapid real-time localization.** *J Am Coll Cardiol* 2003, **41**:1134-1141.
2. Sakuma H, Ichikawa Y, Chino S, Hirano T, Makino K, Takeda K: **Detection of coronary artery stenosis with whole-heart coronary magnetic resonance angiography.** *J Am Coll Cardiol* 2006, **48**:1946-1950.
3. Weber OM, Martin AJ, Higgins CB: **Whole-heart steady-state free precession coronary artery magnetic resonance angiography.** *Magn Reson Med* 2003, **50**:1223-1228.

4. Manning WJ, Edelman RR: **Magnetic resonance coronary angiography.** *Magn Reson Q* 1993, **9**:131-151.
5. Terashima M, Nguyen PK, Rubin GD, Iribarren C, Courtney BK, Go AS, Fortmann SP, McConnell MV: **Impaired coronary vasodilation by magnetic resonance angiography is associated with advanced coronary artery calcification.** *JACC Cardiovasc Imaging* 2008, **1**:167-173.
6. Glagov S, Weisenberg E, Zarins CK, Stankunavicius R, Koletlis GJ: **Compensatory enlargement of human atherosclerotic coronary arteries.** *N Engl J Med* 1987, **316**:1371-1375.
7. Fayad ZA, Fuster V, Fallon JT, Jayasundera T, Worthley SG, Helft G, Aguinaldo JG, Badimon JJ, Sharma SK: **Noninvasive in vivo human coronary artery lumen and wall imaging using black-blood magnetic resonance imaging.** *Circulation* 2000, **102**:506-510.
8. Fernandes JL, Serrano CV Jr, Blotta MH, Coelho OR, Nicolau JC, Avila LF, Rochitte CE, Parga Filho JR: **Regression of coronary artery outward remodeling in patients with non-ST-segment acute coronary syndromes: a longitudinal study using noninvasive magnetic resonance imaging.** *Am Heart J* 2006, **152**:1123-1132.
9. McConnell MV, Meyer CH, Putz EJ, Nishimura DG, Hu BS: **Spiral coronary wall imaging: Patient studies.** *Ninth annual meeting of the International Society for Magnetic Resonance in Medicine; Glasgow, Scotland* 2001, 1969.
10. Kim WY, Stuber M, Bornert P, Kissinger KV, Manning WJ, Botnar RM: **Three-dimensional black-blood cardiac magnetic resonance coronary vessel wall imaging detects positive arterial remodeling in patients with nonsignificant coronary artery disease.** *Circulation* 2002, **106**:296-299.
11. Botnar RM, Stuber M, Kim WY, Danias PG, Manning WJ: **Magnetic resonance coronary lumen and vessel wall imaging.** *Rays* 2001, **26**:291-303.
12. Botnar RM, Stuber M, Kissinger KV, Kim WY, Spuentrup E, Manning WJ: **Noninvasive coronary vessel wall and plaque imaging with magnetic resonance imaging.** *Circulation* 2000, **102**:2582-2587.
13. Kim WY, Astrup AS, Stuber M, Tarnow L, Falk E, Botnar RM, Simonsen C, Pietraszek L, Hansen PR, Manning WJ, et al: **Subclinical coronary and aortic atherosclerosis detected by magnetic resonance imaging in type 1 diabetes with and without diabetic nephropathy.** *Circulation* 2007, **115**:228-235.
14. Miao C, Chen S, Macedo R, Lai S, Liu K, Li D, Wasserman BA, Vogel-Claussen J, Lima JA, Bluemke DA: **Positive remodeling of the coronary arteries detected by magnetic resonance imaging in an asymptomatic population: MESA (Multi-Ethnic Study of Atherosclerosis).** *J Am Coll Cardiol* 2009, **53**:1708-1715.
15. Hlatky MA, Ashley E, Quertermous T, Boothroyd DB, Ridker P, Southwick A, Myers RM, Iribarren C, Fortmann SP, Go AS: **Matrix metalloproteinase circulating levels, genetic polymorphisms, and susceptibility to acute myocardial infarction among patients with coronary artery disease.** *Am Heart J* 2007, **154**:1043-1051.
16. Fair JM, Kiazand A, Varady A, Mahboubia M, Norton L, Rubin GD, Iribarren C, Go AS, Hlatky MA, Fortmann SP: **Ethnic differences in coronary artery calcium in a healthy cohort aged 60 to 69 years.** *Am J Cardiol* 2007, **100**:981-985.
17. Go AS, Iribarren C, Chandra M, Lathon PV, Fortmann SP, Quertermous T, Hlatky MA: **Statin and beta-blocker therapy and the initial presentation of coronary heart disease.** *Ann Intern Med* 2006, **144**:229-238.
18. Iribarren C, Go AS, Husson G, Sidney S, Fair JM, Quertermous T, Hlatky MA, Fortmann SP: **Metabolic syndrome and early-onset coronary artery disease: is the whole greater than its parts?** *J Am Coll Cardiol* 2006, **48**:1800-1807.
19. Iribarren C, Husson G, Go AS, Lo JC, Fair JM, Rubin GD, Hlatky MA, Fortmann SP: **Plasma leptin levels and coronary artery calcification in older adults.** *J Clin Endocrinol Metab* 2007, **92**:729-732.
20. Terashima M, Meyer CH, Keeffe BG, Putz EJ, de la Pena-Almaguer E, Yang PC, Hu BS, Nishimura DG, McConnell MV: **Noninvasive assessment of coronary vasodilation using magnetic resonance angiography.** *J Am Coll Cardiol* 2005, **45**:104-110.
21. Liu X, Zhao X, Huang J, Francois CJ, Tuite D, Bi X, Li D, Carr JC: **Comparison of 3 D free-breathing coronary MR angiography and 64-MDCT angiography for detection of coronary stenosis in patients with high calcium scores.** *AJR Am J Roentgenol* 2007, **189**:1326-1332.
22. Nguyen PK, Meyer C, Engvall J, Yang P, McConnell MV: **Noninvasive assessment of coronary vasodilation using cardiovascular magnetic resonance in patients at high risk for coronary artery disease.** *J Cardiovasc Magn Reson* 2008, **10**:28.
23. Desai MY, Lai S, Barmet C, Weiss RG, Stuber M: **Reproducibility of 3 D free-breathing magnetic resonance coronary vessel wall imaging.** *Eur Heart J* 2005, **26**:2320-2324.
24. Hazirolan T, Gupta SN, Mohamed MA, Bluemke DA: **Reproducibility of black-blood coronary vessel wall MR imaging.** *J Cardiovasc Magn Reson* 2005, **7**:409-413.
25. Macedo R, Chen S, Lai S, Shea S, Malayeri AA, Szklo M, Lima JA, Bluemke DA: **MRI detects increased coronary wall thickness in asymptomatic individuals: the multi-ethnic study of atherosclerosis (MESA).** *J Magn Reson Imaging* 2008, **28**:1108-1115.
26. Schar M, Kim WY, Stuber M, Boesiger P, Manning WJ, Botnar RM: **The impact of spatial resolution and respiratory motion on MR imaging of atherosclerotic plaque.** *J Magn Reson Imaging* 2003, **17**:538-544.
27. Katoh M, Spuentrup E, Buecker A, Manning WJ, Gunther RW, Botnar RM: **MR coronary vessel wall imaging: comparison between radial and spiral k-space sampling.** *J Magn Reson Imaging* 2006, **23**:757-762.
28. Koktzoglou I, Simonetti O, Li D: **Coronary artery wall imaging: initial experience at 3 Tesla.** *J Magn Reson Imaging* 2005, **21**:128-132.
29. Botnar RM, Stuber M, Lamerichs R, Smink J, Fischer SE, Harvey P, Manning WJ: **Initial experiences with in vivo right coronary artery human MR vessel wall imaging at 3 tesla.** *J Cardiovasc Magn Reson* 2003, **5**:589-594.
30. Priest AN, Bansmann PM, Kaul MG, Stork A, Adam G: **Magnetic resonance imaging of the coronary vessel wall at 3 T using an obliquely oriented reinversion slab with adiabatic pulses.** *Magn Reson Med* 2005, **54**:1115-1122.
31. Priest AN, Bansmann PM, Mullerleile K, Adam G: **Coronary vessel-wall and lumen imaging using radial k-space acquisition with MRI at 3 Tesla.** *Eur Radiol* 2007, **17**:339-346.
32. Goraya TY, Leibson CL, Palumbo PJ, Weston SA, Killian JM, Pfeifer EA, Jacobsen SJ, Frye RL, Roger VL: **Coronary atherosclerosis in diabetes mellitus: a population-based autopsy study.** *J Am Coll Cardiol* 2002, **40**:946-953.
33. Hoff JA, Quinn L, Sevrukov A, Lipton RB, Daviglius M, Garside DB, Ajmure NK, Gandhi S, Kondos GT: **The prevalence of coronary artery calcium among diabetic individuals without known coronary artery disease.** *J Am Coll Cardiol* 2003, **41**:1008-1012.
34. Arad Y, Newstein D, Cadet F, Roth M, Guerci AD: **Association of multiple risk factors and insulin resistance with increased prevalence of asymptomatic coronary artery disease by an electron-beam computed tomographic study.** *Arterioscler Thromb Vasc Biol* 2001, **21**:2051-2058.
35. Detrano R, Guerci AD, Carr JJ, Bild DE, Burke G, Folsom AR, Liu K, Shea S, Szklo M, Bluemke DA, et al: **Coronary calcium as a predictor of coronary events in four racial or ethnic groups.** *N Engl J Med* 2008, **358**:1336-1345.
36. Rumberger JA, Simons DB, Fitzpatrick LA, Sheedy PF, Schwartz RS: **Coronary artery calcium area by electron-beam computed tomography and coronary atherosclerotic plaque area. A histopathologic correlative study.** *Circulation* 1995, **92**:2157-2162.

doi:10.1186/1532-429X-12-75

Cite this article as: Terashima et al: Right coronary wall cmr in the older asymptomatic advance cohort: positive remodeling and associations with type 2 diabetes and coronary calcium. *Journal of Cardiovascular Magnetic Resonance* 2010 **12**:75.