

Poster presentation

Comparison of strain-encoded cardiac MRI images with different k-space acquisition strategies

El-Sayed H Ibrahim^{*1}, Wolfgang Rehwald², Sven Zuehlsdorff² and Richard D White¹

Address: ¹University of Florida College of Medicine, Jacksonville, FL, USA and ²Siemens AG Healthcare Sector-Cardiovascular MR Research and Development, Chicago, IL, USA

* Corresponding author

from 13th Annual SCMR Scientific Sessions
Phoenix, AZ, USA. 21-24 January 2010

Published: 21 January 2010

Journal of Cardiovascular Magnetic Resonance 2010, 12(Suppl 1):P93 doi:10.1186/1532-429X-12-S1-P93

This abstract is available from: <http://jcmr-online.com/content/12/S1/P93>

© 2010 Ibrahim et al; licensee BioMed Central Ltd.

Introduction

Strain encoding (SENC) is a newly-developed MRI technique for measuring myocardial strain in the through-plane direction [1]. With conventional k-space acquisition, SENC requires two separate acquisitions to obtain two sets of images (low-tune (LT) and high-tune (HT)), which are combined to obtain the strain image. Non-Cartesian k-space trajectories are becoming more popular because they allow for data undersampling with acceptable image quality [2]. In this work, SENC was combined with undersampled radial k-space acquisition and interleaved SENC tunings to reduce scan time to one breath-hold. The results were compared to conventional SENC images.

Methods

Three volunteers were scanned on 3 T MRI system (Siemens TIM-TRIO, Erlangen, Germany). Four SENC scans were conducted in four separate breath-holds. Conventional SENC pulse sequence was run in the first and second scans: in the first scan, a set of cine LT images was acquired with Cartesian k-space (no undersampling). The second scan was the same as the first scan, but with HT images. In the third scan, the modified SENC sequence (Fig. 1) was used: interleaved LT and HT tunings with radial undersampling (60%). The fourth scan was a repetition of the third scan, but with Cartesian undersampling instead of radial (same ratio), for comparison. In all scans,

ramped flip-angle was used to maintain constant signal intensity. Pixel size $\sim 1.5 \text{ mm}^2$ and scan-time $\sim 20 \text{ s}$.

The LT and HT images were combined in an interleaved fashion (view-sharing) to result in strain images (about 26 phases). Signal-to-noise ratio (SNR) was measured in each image by dividing mean myocardial signal intensity by

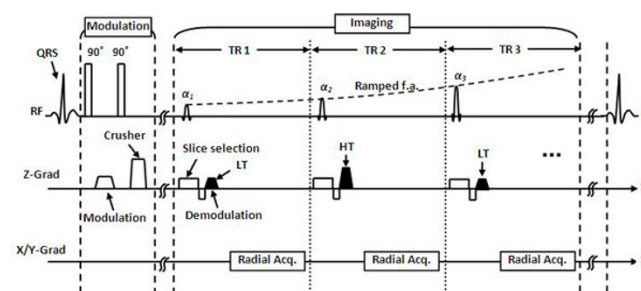


Figure 1
Modified SENC pulse sequence. The sequence consists of two sections: modulation and imaging. Magnetization is modulated using non-selective 90°-90° RF pulses with z-gradient in-between. During imaging, alternating low-tuning (LT) and high-tuning (HT) demodulations are implemented. Radial k-space reading is used with 60% undersampling. Imaging RF pulses are ramped during the cardiac cycle to compensate for modulation fading.




Figure 2
Short-axis SENC images showing longitudinal strain at the same heart phase. Radial (left) and Cartesian (right) acquisition. Arrows point to high-strain inferior and low-strain anterior LV myocardium. Dotted arrows point to RV. The radial image as acceptable image quality and acquired in half the time as the Cartesian.

standard-deviation of background noise. Longitudinal strain values were calculated at the same position and cardiac-phase from corresponding Cartesian and radial images. Bland-Altman analysis[3] was conducted.

Results

Fig. 2 shows the resulting strain images. The undersampled radial images show similar image quality to conventional Cartesian images. No streak artifacts were observed. The undersampled Cartesian images(scan#4) resulted in much deteriorated image quality. SNR was 20 and 16 for

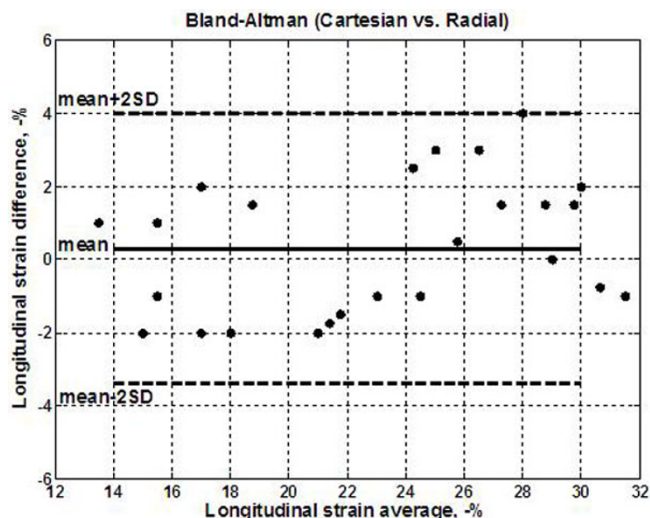


Figure 3
Bland-Altman plot for the correlation between myocardial longitudinal strain from Cartesian and radial SENC images. The plot shows no significant bias between the two methods. All points lie within the $\pm 2SD$ margin.

Cartesian and radial images, respectively. Bland-Altman(Fig. 3) shows no significant difference in strain measurement between the two methods (differences lie within $\pm 2SD$ limits).

Discussion and conclusions

Radial k-space acquisition allows for SENC imaging in one breath-hold with satisfactory image quality. Image misregistration artifacts are minimized using the proposed method. The high-field 3Tesla system compensates for SNR loss associated with reduced data acquisition. Employing the same undersampling ratio with Cartesian acquisition results in deteriorated image quality and introduces artifacts. Future studies will address implementing 3D radial acquisition to improve SNR.

References

1. Osman : *MRM* **46**:324-334.
2. Shankaranarayanan : *Radiology* **21**:827-836.
3. Altman : *Statistician* **32**:307-317.

Publish with **BioMed Central** and every scientist can read your work free of charge

"BioMed Central will be the most significant development for disseminating the results of biomedical research in our lifetime."

Sir Paul Nurse, Cancer Research UK

Your research papers will be:

- available free of charge to the entire biomedical community
- peer reviewed and published immediately upon acceptance
- cited in PubMed and archived on PubMed Central
- yours — you keep the copyright

Submit your manuscript here:
http://www.biomedcentral.com/info/publishing_adv.asp