

POSTER PRESENTATION

Open Access

Time-resolved mr venography pre catheter-based ablation for atrial fibrillation

Michael Schonberger*, Aya Kino, Andrada Popescu, Maurizio Galizia, Jeremy Collins, Timothy Carroll, James Carr

From 2011 SCMR/Euro CMR Joint Scientific Sessions
Nice, France. 3-6 February 2011

Objective

The purpose of this study was to evaluate Time-resolved MR venography (TR-MRV) of the pulmonary venous circulation using the time-resolved angiography with interleaved stochastic trajectories (TWIST) method of time-resolved MRA (TR-MRA) and compare it with the more commonly used conventional Contrast enhanced magnetic resonance angiography (CE-MRA) approach in atrial fibrillation patients referred for pre-ablation pulmonary vein mapping.

Background

Catheter-based ablation of the pulmonary veins prevents recurrence of atrial fibrillation in 70-80% of patients during the first year of follow-up^{1,2}. CE-MRA depicts the left atrium and pulmonary veins with high spatial resolution, enabling accurate measurement of pulmonary vein ostia to be made with depiction of their relationship to other structures.^{1,3} Conventional CE-MRA however requires timing of contrast enhancement and produces images with overlap of venous and arterial structures, potentially obscuring pulmonary vein ostia. TR-MRA is an alternative to conventional CE-MRA and has been used successfully in other vascular territories.⁴ Such an approach may be particularly advantageous in the pulmonary circulation with its rapid arteriovenous transit time, allowing acquisition of pure pulmonary venous phase images with a simpler imaging protocol.

Material and methods

26 patients (15 males; age 60.0 ± 12.7y) referred for pre-ablation pulmonary vein mapping underwent both conventional CE-MRA and TR-MRV with TWIST. Imaging was performed on a 1.5 Tesla (MAGNETOM Avanto, Siemens Healthcare) MRI scanner. Source partition and

MIP images were evaluated. **Quantitative Analysis:** Pulmonary vein ostium orthogonal dimensions were measured using double oblique multiplanar reformatting. **Qualitative Analysis:** For qualitative analysis, both source partition images and MIP images were assessed by two observers. Pulmonary vein conspicuity was scored on a scale of 1-4 (1=poor, 2=fair, 3=good, 4=excellent). The number of pulmonary veins (3 veins=common ostium, 4 veins = normal, 5 veins=accessory vein) was recorded.

Results

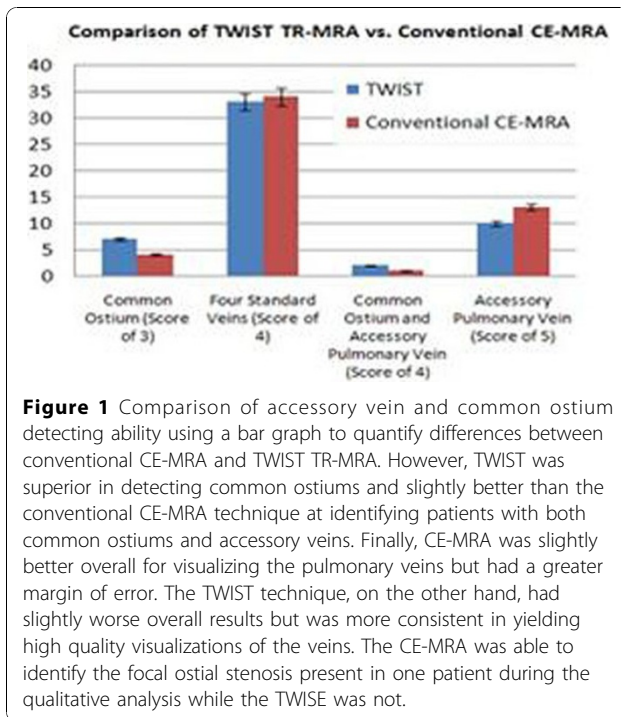
Orthogonal venous diameters were comparable for both TR-MRV and conventional CEMRA (1.34cm ± 0.37 vs 1.38cm ± 0.36, respectively); see Table 1. Visualization

Table 1 Comparison of the mean pulmonary diameter ± standard deviation (maximum; minimum values for TWIST and Conventional CE-MRA respectively)

	TWIST (Time-Resolved MRA)	Conventional CE-MRA	P-values
RUPV			
cc	1.58 ± 0.27 (2.08;1.2)	1.68 ± 0.24 (2.08;1.13)	0.069
ap	1.13 ± 0.23 (1.52;0.63)	1.16 ± 0.19 (1.66;0.88)	0.521
RLPV			
cc	1.69 ± 0.19 (2.06;1.41)	1.72 ± 0.16 (2.14;1.49)	0.307
ap	1.22 ± 0.23 (1.65;0.79)	1.32 ± 0.24 (1.84;0.98)	0.005
LUPV			
cc	1.51 ± 0.33 (2.14;0.47)	1.53 ± 0.31 (2.26;0.59)	0.456
ap	1.05 ± 0.28 (1.73;0.35)	1.09 ± 0.25 (1.69;0.53)	0.168
LLPV			
cc	1.54 ± 0.33 (2.64;1.04)	1.57 ± 0.28 (2.34;1.1)	0.573
ap	1.00 ± 0.27 (1.63;0.52)	0.97 ± 0.23 (1.47;0.49)	0.286

All values in cm. cc = measures in cranial-caudal direction; ap = measures in anterior-posterior direction. The t-test revealed a value of 0.004933 which is much less than the level for statistical significance of 0.05. Therefore, the difference between the measuring ability of TWIST and Conventional CE-MRA is not statistically significant.

Northwestern University, Chicago, IL, USA



of pulmonary vein anatomy and variant anatomy was also similar for both techniques (fig 1).

Conclusion

We have demonstrated that TR-MRV using TWIST produces comparable anatomic images and pulmonary venous dimensions to the more widely used CEMRA technique. TR-MRV improves arterio-venous separation producing high resolution pulmonary venous phase images without arterial overlap.

Published: 2 February 2011

References

1. Hauser TH, et al: *Europace* 2008.
2. Wattigney WA, et al: *Circulation* 2003.
3. Maksimovi R, et al: *European Radiology* 2006.
4. Kim CY, et al: *AJR* 2008.

doi:10.1186/1532-429X-13-S1-P234

Cite this article as: Schonberger et al: Time-resolved mr venography pre catheter-based ablation for atrial fibrillation. *Journal of Cardiovascular Magnetic Resonance* 2011 **13**(Suppl 1):P234.

Submit your next manuscript to BioMed Central and take full advantage of:

- Convenient online submission
- Thorough peer review
- No space constraints or color figure charges
- Immediate publication on acceptance
- Inclusion in PubMed, CAS, Scopus and Google Scholar
- Research which is freely available for redistribution

Submit your manuscript at
www.biomedcentral.com/submit

