

POSTER PRESENTATION

Open Access

# Cardiac MRI for evaluation of paravalvular leak after Transcatheter Aortic Valve Replacement

Chesnal D Arepalli<sup>2\*</sup>, Raul R Blanco<sup>1</sup>, Mihir Kanitkar<sup>1</sup>, John N Oshinski<sup>2</sup>, Vasilis C Babaliaros<sup>1</sup>, Peter C Block<sup>1</sup>, Vinod Thourani<sup>3</sup>, Robert A Guyton<sup>3</sup>, Arthur E Stillman<sup>2</sup>, Stamatios Lerakis<sup>1</sup>

From 16th Annual SCMR Scientific Sessions  
San Francisco, CA, USA. 31 January - 3 February 2013

## Background

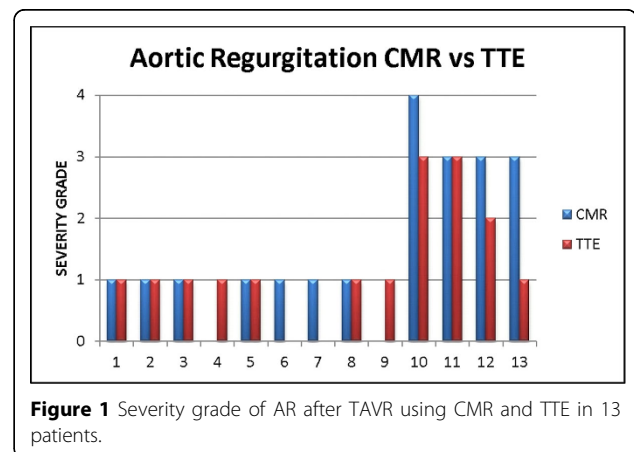
The most common complication of Transcatheter Aortic Valve Replacement (TAVR) is aortic regurgitation (AR). Typically, this regurgitation is in the mild range, yet in a smaller subset AR could be in the moderate-severe range. Significant regurgitation is usually due to paravalvular leak due to undersizing of the valve or malposition inferiorly into the left ventricular outflow tract or superiorly into the aorta during deployment. Transthoracic Echocardiography (TTE) is first line test for the amount of regurgitation, but can be flawed due to poor acoustic windows and eccentricity of the paravalvular leak. Cardiac MRI (CMR) may be used to assess the aortic regurgitation when there is a discrepancy with echocardiography or imaging of the valve is in question.

## Methods

We examined 13 patients who underwent TAVR as part of the PARTNER trial and subsequently had a CMR for evaluation of aortic regurgitation (figure 1). Total AR (valvular and paravalvular) was graded by CMR using flow quantitation as 0 (<1% Regurgitant Fraction), 1 (1-29%), 2 (30-39%), 3 (40-49%) and 4 (>50%). Total AR was graded by TTE using color doppler as 0 (none), 1 (trivial or mild), 2 (moderate), 3 (moderate severe) or 4 (severe).

## Results

Typical for PARTNER trial demographics, mean age is 87 +/- 5 years with 11 males. Aortic Regurgitation was predominantly paravalvular. In 12 of the 13 patients TTE was able to accurately assess severity of aortic regurgitation within 1 severity grade as compared to CMR. In 1 patient, echocardiography diagnosed mild AR despite



**Figure 1** Severity grade of AR after TAVR using CMR and TTE in 13 patients.

good windows and doppler studies while CMR regurgitant fraction was 45% in the moderate-severe range.

## Conclusions

CMR may provide an accurate assessment of aortic regurgitant fraction after TAVR when physical exam and echocardiographic evidence is noncongruent.

## Funding

None.

## Author details

<sup>1</sup>Cardiology, Emory University, Atlanta, GA, USA. <sup>2</sup>Radiology, Emory University, Atlanta, GA, USA. <sup>3</sup>Cardiothoracic Surgery, Emory University, Atlanta, GA, USA.

Published: 30 January 2013

<sup>2</sup>Radiology, Emory University, Atlanta, GA, USA  
Full list of author information is available at the end of the article

doi:10.1186/1532-429X-15-S1-P60

**Cite this article as:** Arepalli et al.: Cardiac MRI for evaluation of paravalvular leak after Transcatheter Aortic Valve Replacement. *Journal of Cardiovascular Magnetic Resonance* 2013 **15**(Suppl 1):P60.

**Submit your next manuscript to BioMed Central and take full advantage of:**

- Convenient online submission
- Thorough peer review
- No space constraints or color figure charges
- Immediate publication on acceptance
- Inclusion in PubMed, CAS, Scopus and Google Scholar
- Research which is freely available for redistribution

Submit your manuscript at  
[www.biomedcentral.com/submit](http://www.biomedcentral.com/submit)

