

POSTER PRESENTATION

Open Access

Real-time flow assessment: From model to patients

Julius Traber^{1*}, Lennart Wurche¹, Matthias A Dieringer¹, Wolfgang Utz¹, Andreas Greiser², Ning Jin³, Philipp Barckow⁴, Jeanette Schulz-Menger¹

From 17th Annual SCMR Scientific Sessions
New Orleans, LA, USA. 16-19 January 2014

Background

In stratification of heart valve diseases blood flow assessment often plays a key role. When echocardiography struggles, phase contrast magnetic resonance imaging (PC-MRI) may be considered as an alternative (Srichai et al. *AJR* 2009). Arrhythmias are a major limitation of conventional segmented PC-MRI (SEG). Real-time sequences (RT) could overcome it. The purpose of this study is to evaluate RT in a flow model as well as in volunteers and patients. We hypothesize to measure equal velocities and flow compared to SEG as reference in sinus rhythm and aimed to show feasibility in atrial fibrillation (Afib).

Methods

In a flow model (I), volunteers and prospectively enrolled patients (II) we compared a highly accelerated RT (temp. res. 40 ms, TE 5.6 ms, ETL 7, T-PAT 3 \times , matrix 128 \times 104px) using shared velocity encoding (Lin et al. *MRM* 2009) with SEG (temp. res. 48 ms, TE 2.3 ms, ETL 5, I-PAT 2 \times , matrix 192 \times 156px) on a 1.5 T scanner (Avanto, Siemens Healthcare, Germany) with a 12 channel cardiac coil. I The model generated adjustable constant flow. 81 PC images were acquired 25 mm from an interchangeable aortic stenosis-like narrowing with different areas (0.6 cm², 1.3 cm², 2.0 cm²) perpendicular to tube running (Figure 1). II In vivo studies were measured at sinotubular junction perpendicular to the aorta. We quantified (cvi42, Circle CVI, Canada) with equalized voxel size: in I mean velocity and flow in II mean peak velocity, stroke volume and regurgitation fraction In patients with Afib only RT was applied.

Results

I All PC images were acquired successfully and evaluable. Mean velocities ranged 35-216 cm/s (SEG). Scatter plots showed good correlations between SEG and RT (velocity: $r = 0.991$, $p < 0.0005$; flow: $r > 0.993$, $p < 0.0005$). Flow in RT partially strayed to higher values, although differences were not significant (122 ± 72 ml/s vs. 143 ± 74 ml/s; $p = 0.290$). II We included 119 subjects: 52 healthy subjects (28 men, 51 ± 19 y) as well as patients (55 men, 66 ± 15 y) with aortic valve disease (60) and/or Afib (8). RT acquisition failed in one, image quality was non-diagnostic in three cases. Peak velocities ranged 64-373 cm/s (SEG). Scatter plots showed reasonable correlations between SEG and RT (velocity: $r = 0.964$, $p < 0.0005$; stroke volume $r = 0.880$, $p < 0.0005$). Velocities in RT partially strayed to lower values on high reference velocities, although differences were not significant (164 ± 71 cm/s vs. 153 ± 60 cm/s; $p = 0.206$). Stray bullets had at least moderate aortic valve stenosis. In patients with aortic valve insufficiency (47), regurgitation fractions correlated well ($r = 0.937$; $p = 0.0005$). In Afib patients PC-RT was feasible in all patients and flow-time plots showed frequency-dependent variability of stroke volumes (Figure 2).

Conclusions

The evaluated real-time PC sequence can access flow reliably and in good correlation to a conventional segmented version in model experiments, volunteers and patients. Hence it might become an useful alternative to doppler echocardiography in arrhythmic patients.

Funding

Funded by the general research budget of the working group.

¹Working Group on Cardiovascular Magnetic Resonance Imaging of Experimental and Clinical Research Center/Department of Cardiology and Nephrology, Charité Campus Buch/HELIOS Klinikum Berlin-Buch, Berlin, Germany

Full list of author information is available at the end of the article

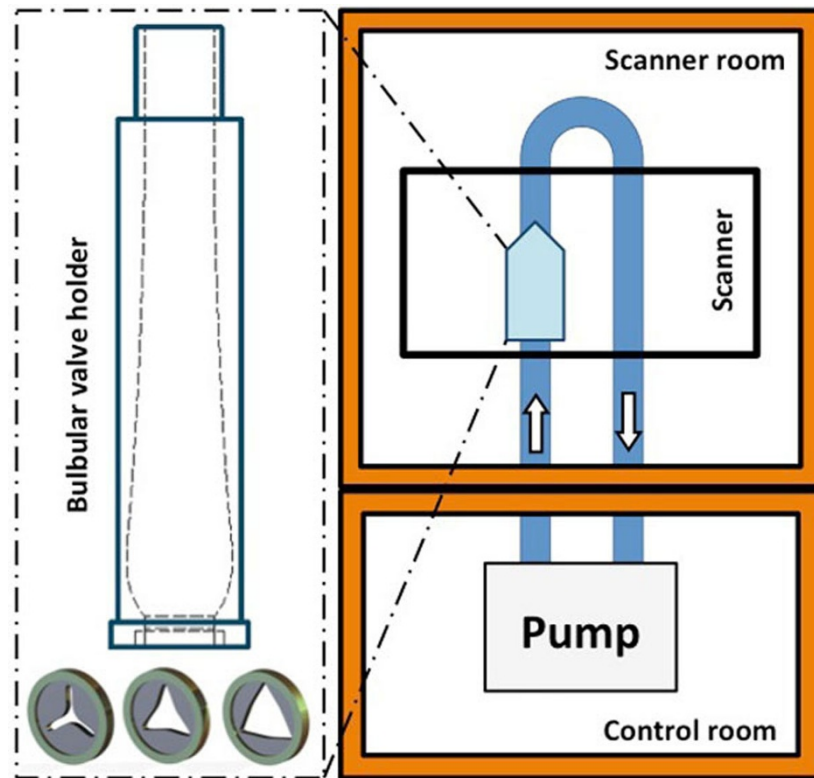


Figure 1 Flow model set-up: Adjustable pump generates constant flow; measurements 25 mm behind interchangeable aortic stenosis-like narrowings.

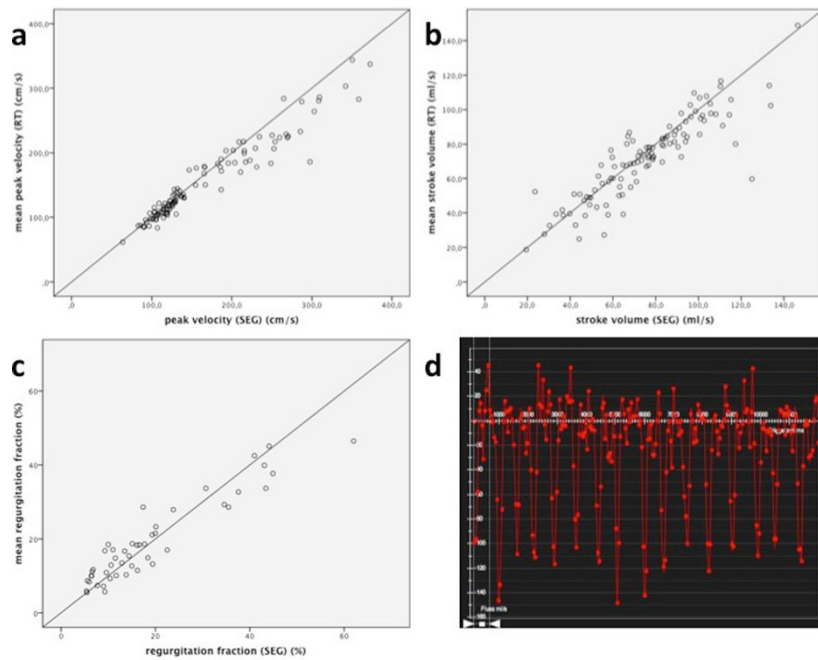


Figure 2 In vivo results: RT shows good correlation to SEG regarding peak velocity (a), stroke volume (b) and regurgitation fraction (c). Stray bullets had at least moderate aortic valve stenosis. On Afib RT shows frequency-dependent variability of stroke volumes (d).

Authors' details

¹Working Group on Cardiovascular Magnetic Resonance Imaging of Experimental and Clinical Research Center/Department of Cardiology and Nephrology, Charité Campus Buch/HELIOS Klinikum Berlin-Buch, Berlin, Germany. ²Healthcare Sector, Siemens AG, Erlangen, Germany. ³Medical Solutions, Siemens USA Inc., Columbus, Ohio, USA. ⁴Circle Cardiovascular Imaging Inc., Calgary, Alberta, Canada.

Published: 16 January 2014

doi:10.1186/1532-429X-16-S1-P386

Cite this article as: Traber et al.: Real-time flow assessment: From model to patients. *Journal of Cardiovascular Magnetic Resonance* 2014 **16** (Suppl 1):P386.

**Submit your next manuscript to BioMed Central
and take full advantage of:**

- Convenient online submission
- Thorough peer review
- No space constraints or color figure charges
- Immediate publication on acceptance
- Inclusion in PubMed, CAS, Scopus and Google Scholar
- Research which is freely available for redistribution

Submit your manuscript at
www.biomedcentral.com/submit

