

ORAL PRESENTATION

Open Access

# Visual detection and characterization of chronic myocardial infarctions in patients using native T<sub>1</sub> maps at 3T

Avinash Kali<sup>1\*</sup>, Eui-Young Choi<sup>2</sup>, Behzad Sharif<sup>1</sup>, Young Jin Kim<sup>2</sup>, Xiaoming Bi<sup>3</sup>, Bruce S Spottiswoode<sup>3</sup>, Ivan Cokic<sup>1</sup>, Hsin-Jung Yang<sup>1</sup>, Mourad Tighiouart<sup>1</sup>, Debiao Li<sup>1</sup>, Daniel S Berman<sup>1</sup>, Byoung Wook Choi<sup>2</sup>, Hyuk-Jae Chang<sup>2</sup>, Rohan Dharmakumar<sup>1</sup>

From 18th Annual SCMR Scientific Sessions  
Nice, France. 4-7 February 2015

## Background

Late Gadolinium Enhancement (LGE) Cardiovascular Magnetic Resonance (CMR) is routinely used for characterizing chronic myocardial infarctions (cMIs), but it is contraindicated in patients with end-stage chronic kidney disease. We investigated whether native T<sub>1</sub> mapping at 3T can be used to detect and characterize cMIs in patients with prior STEMI and NSTEMI.

## Methods

Breath-held 2D native T<sub>1</sub> maps (8 TIs with 2 Look-Locker cycles of 3+5 images; minimum TI = 120ms; TI increment = 80 ms; flip angle = 35°; bandwidth = 1085 Hz/pixel; voxel size = 1.5x1.5x8mm<sup>3</sup>) and LGE images (IR-prepared FLASH; optimal TI to null remote myocardium; TR/TE = 6.54/3.27ms; flip angle = 20°; bandwidth = 460 Hz/pixel; voxel size = 1.2x1.2x8mm<sup>3</sup>) were acquired in patients with prior STEMI (n=15) and NSTEMI (n=17) at 3T at a median of 13.6 years after acute MI. cMI location, size and transmuralities were determined using Mean+5SD criterion relative to remote myocardium. Visual detection of cMI territories on LGE images and T<sub>1</sub> maps were assessed by two independent reviewers.

## Results

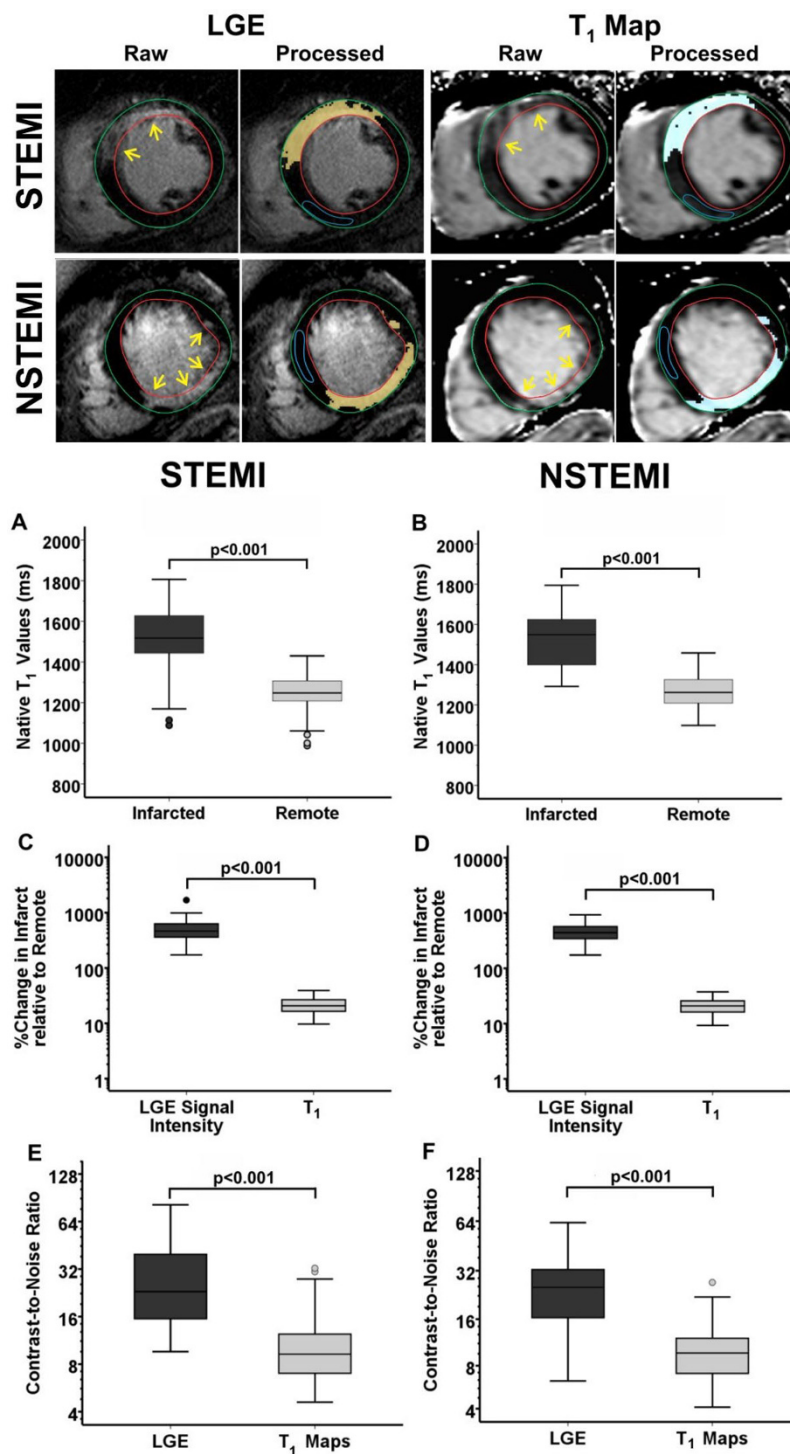
Representative native T<sub>1</sub> maps and LGE images from two patients, one with prior STEMI, and one with prior NSTEMI are shown in Fig. 1. Relative to remote myocardium, median T<sub>1</sub> of the cMI was 271ms higher in STEMI patients (Infarct: 1517ms; Remote: 1247ms;

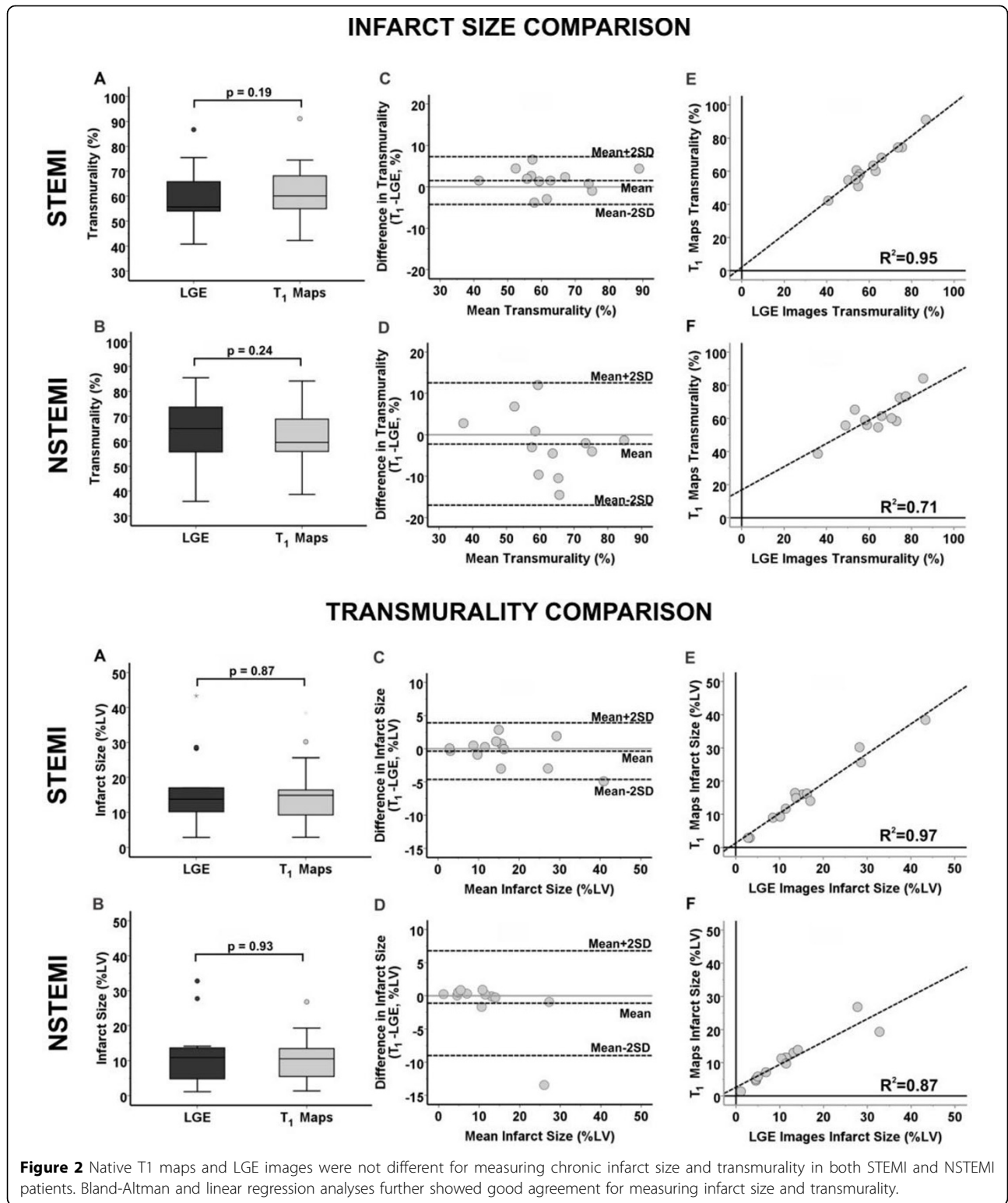
p<0.001; Fig. 1), and 229ms higher in NSTEMI patients (Infarct: 1549ms, Remote: 1262ms; p<0.001; Fig. 1). Median percentage change in LGE signal intensity (LGE-SI) of the cMI relative to remote myocardium was significantly higher than that of percentage change in T<sub>1</sub> in both STEMI (LGE: 465%, T<sub>1</sub>: 21%; p<0.001) and NSTEMI (LGE: 441%, T<sub>1</sub>: 20%; p<0.001) patients. Median CNR of LGE images was also 2.5-fold higher relative to that of T<sub>1</sub> maps in both STEMI (LGE: 23.1; T<sub>1</sub>: 9.2; p<0.001) and NSTEMI (LGE: 25.3; T<sub>1</sub>: 9.7; p<0.001) patients. LGE images and native T<sub>1</sub> maps were not different for measuring cMI size (STEMI - LGE: 13.8%; T<sub>1</sub>: 14.9%; p=0.87; NSTEMI - LGE: 10.9%; T<sub>1</sub>: 10.5%; p=0.93; Fig. 2) and transmuralities (STEMI - LGE: 55.6%; T<sub>1</sub>: 60.1%; p=0.19; NSTEMI - LGE: 64.3%; T<sub>1</sub>: 60.9%; p=0.24). Statistical analyses showed good agreement between LGE images and T<sub>1</sub> maps for measuring cMI size (STEMI: bias=-0.4±2.1%; R<sup>2</sup>=0.97; NSTEMI: bias=-1.1±3.9%; R<sup>2</sup>=0.87) and transmuralities (STEMI: bias=1.5±2.9%; R<sup>2</sup>=0.99; NSTEMI: bias=-2.2±7.4%; R<sup>2</sup>=0.71). Sensitivity and specificity of native T<sub>1</sub> maps for detecting cMIs based on threshold criterion were 93% and 97% respectively (STEMI); and 93% and 92% respectively (NSTEMI). Sensitivity and specificity of native T<sub>1</sub> maps for visual detection of cMI were: 61% and 85% (STEMI); and 67% and 90% (NSTEMI).

## Conclusions

Native T<sub>1</sub> maps can reliably detect and characterize cMIs in STEMI and NSTEMI patients when the location of remote myocardium is known. Further increase in image contrast may be necessary to improve visual

<sup>1</sup>Cedars-Sinai Medical Center, Los Angeles, CA, USA  
Full list of author information is available at the end of the article





detection sensitivity of chronic MI territories to the levels observed with LGE.

### Funding

National Heart, Lung, and Blood Institute (RO1 HL091989) and American Heart Association Pre-Doctoral Fellowship (13PRE17210049).

### Authors' details

<sup>1</sup>Cedars-Sinai Medical Center, Los Angeles, CA, USA. <sup>2</sup>Yonsei University College of Medicine, Seoul, Korea (the Republic of. <sup>3</sup>Siemens Healthcare, Los Angeles, CA, USA.

Published: 3 February 2015

doi:10.1186/1532-429X-17-S1-O74

**Cite this article as:** Kali *et al.*: Visual detection and characterization of chronic myocardial infarctions in patients using native T<sub>1</sub> maps at 3T. *Journal of Cardiovascular Magnetic Resonance* 2015 **17**(Suppl 1):O74.

**Submit your next manuscript to BioMed Central and take full advantage of:**

- Convenient online submission
- Thorough peer review
- No space constraints or color figure charges
- Immediate publication on acceptance
- Inclusion in PubMed, CAS, Scopus and Google Scholar
- Research which is freely available for redistribution

Submit your manuscript at  
[www.biomedcentral.com/submit](http://www.biomedcentral.com/submit)

