

WALKING POSTER PRESENTATION

Open Access

It's not just the mitral valve - abnormal motion of the whole aorto-mitral apparatus occurs in both overt and subclinical hypertrophic cardiomyopathy

Chinwe Obianyo^{1,2*}, Gaby Captur^{1,2}, Petros Syrris¹, Luis Lopes^{1,3}, Vimal Patel¹, Patricia Reant⁴, Mariana Mirabel⁵, Charlotte Manisty^{1,2}, Paul Bassett², Daniel Sado^{1,6}, Phillippa Talmud¹, Perry M Elliott^{1,2}, James C Moon^{1,2}

From 19th Annual SCMR Scientific Sessions
Los Angeles, CA, USA. 27-30 January 2016

Background

Mitral valve abnormalities are an important cause of patient morbidity in hypertrophic cardiomyopathy (HCM) contributing to left ventricular outflow tract obstruction (LVOTO). Anterior mitral valve leaflet (AMVL) elongation predisposes to LVOTO. CMR detects this in overt HCM and in sarcomere gene mutation carriers without left ventricular hypertrophy (G+LVH-). However, the geometry of the mitral valve, the subvalvular apparatus and the LVOT is more complex. The purpose of this study was analyse the whole aorto-mitral area (the aorto-mitral apparatus) and track its dynamic motion to explore mechanisms involved in LVOTO-predisposition in subclinical HCM.

Methods

CMR using a 1.5-tesla scanner (Avanto, Siemens) was performed on 35 G+LVH- patients without left atrial (LA) enlargement (31 ± 14 years, 34% male), 31 patients with a clinical diagnosis of HCM with preserved ejection fraction (47 ± 12 years, 61% male, all with pathogenic/likely pathogenic sarcomere mutations [G+LVH+]), and 53 matched healthy volunteers (45% male, 42 ± 14). Direct assessment of the aortomitral apparatus was performed on the 3-chamber view acquired using a breath-held steady-state free precession sequence. Cines were interrogated frame-by-frame, semi-automatically using an in-house script developed for MATLAB[®]. The motion tracking software interactively assigned, tracked and graphed, the dynamic excursion of 4 pre-defined aortomitral regions of interest (ROI) throughout one

cardiac cycle: ROI₁ - hinge point of the posterior MVL; ROI₂ - intertrigonal mitral annulus; ROI₃ - tip of the AMVL; ROI₄ - anterior aortic annulus (Fig. 1).

Results

Qualitative examination of normalized two-dimensional displacement-versus-time plots in G+LVH- patients revealed subtle systolic anterior motion (SAM) of the intertrigonal mitral annulus and reduced longitudinal excursion compared to controls. Statistically significant differences were present for ROI₁ ($P = 0.005$), ROI₂ ($P = 0.01$) and ROI₄ ($P < 0.0001$, Fig. 1). In G+LVH+ patients, displacement-versus-time plots for all 4 ROIs differed significantly from those of controls resulting from a combination of SAM, diminished longitudinal excursion and blunted end-diastolic motion (Fig. 2): ROI₁ ($P = 0.02$), ROI₂ ($P = 0.007$), ROI₃ ($P < 0.0001$) and ROI₄ ($P < 0.0001$).

Conclusions

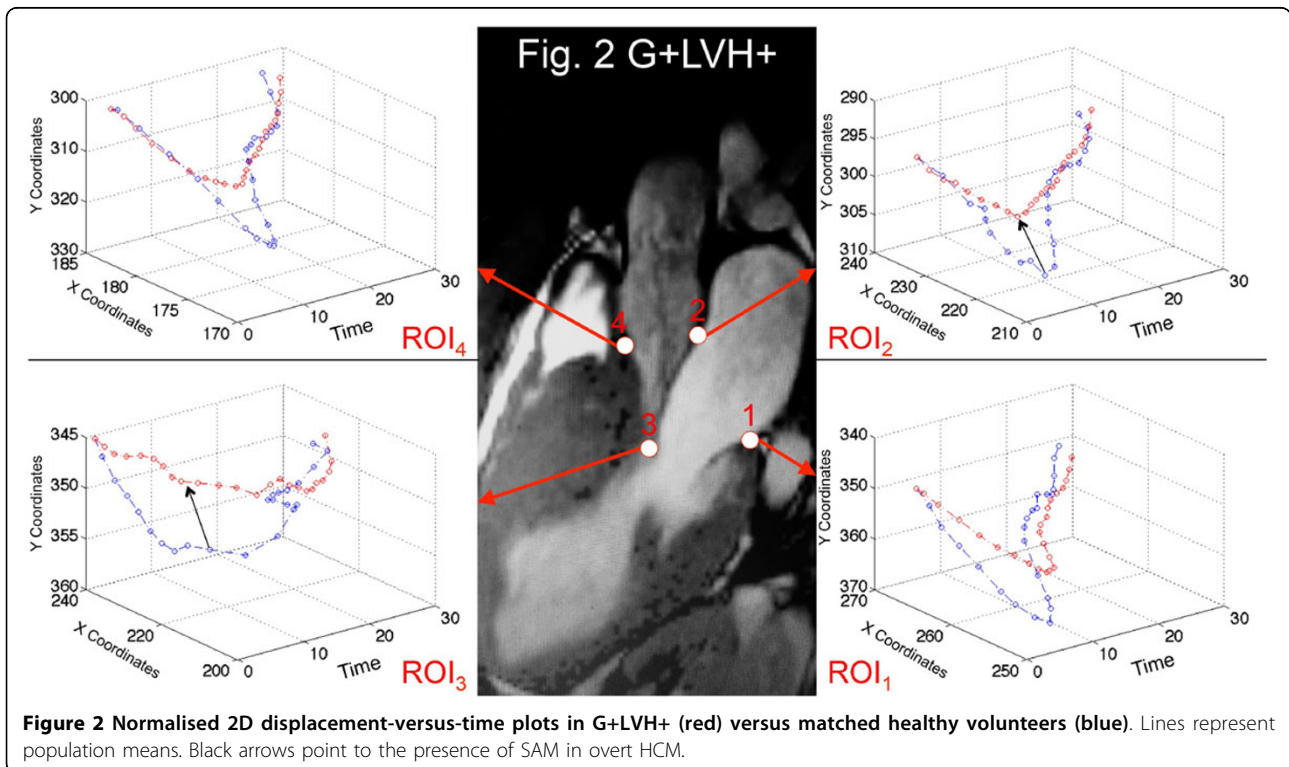
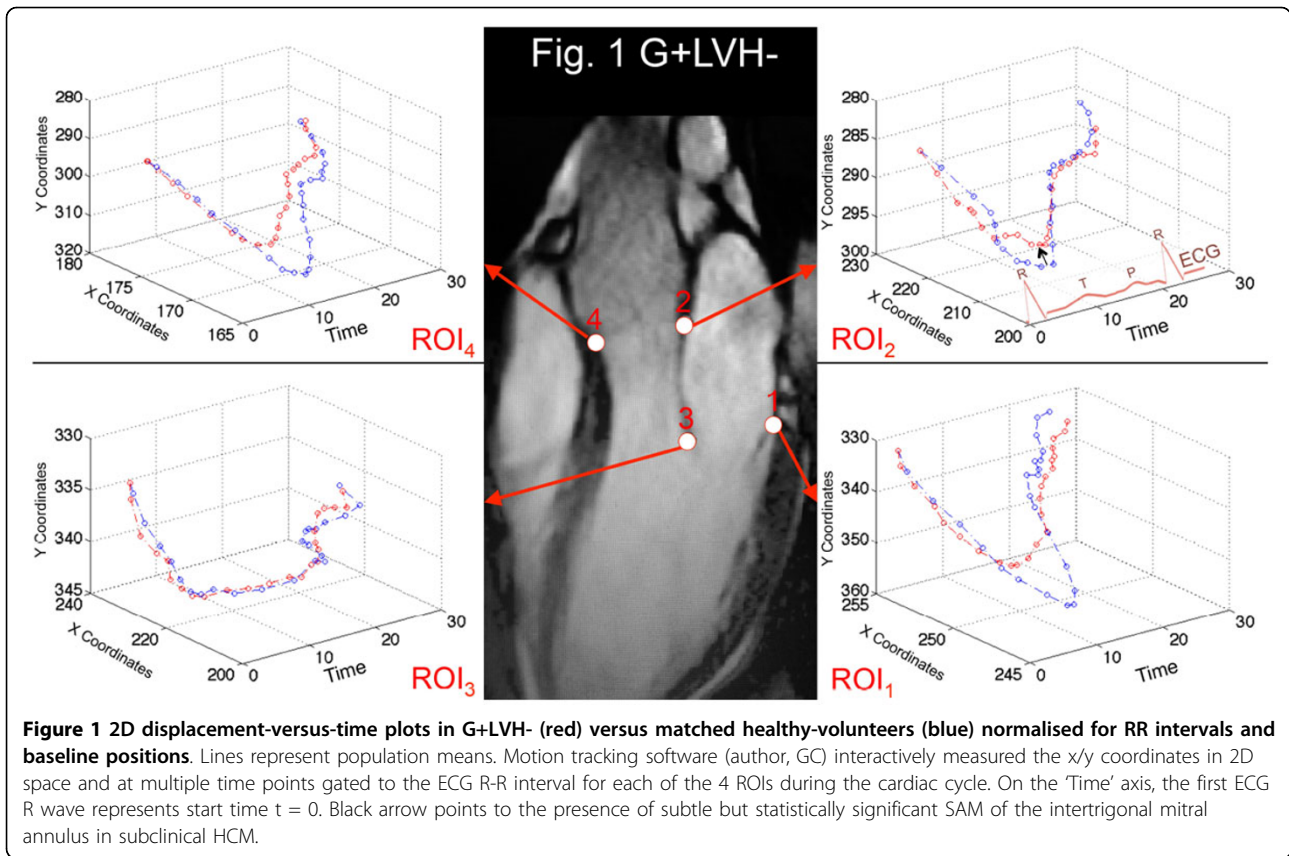
The AMVL is longer in preclinical HCM, but in addition, there are more widespread abnormalities of the aorto-mitral apparatus motion, including SAM of the mitral annulus before the development of LVH or LA enlargement. These data have the potential to improve our understanding of early phenotype development and LVOTO-predisposition in HCM.

Authors' details

¹Institute of Cardiovascular Science, University College London, London, United Kingdom. ²Bart's Heart Centre and Centre for Biostatistics and Epidemiology, London, United Kingdom. ³Cardiovascular centre, University of Lisbon, Lisbon, Portugal. ⁴University of Bordeaux, CHU de Bordeaux, Bordeaux, France. ⁵Assistance Publique-Hôpitaux de Paris, Hôpital Européen

¹Institute of Cardiovascular Science, University College London, London, United Kingdom

Full list of author information is available at the end of the article



Georges Pompidou, Paris, France. ⁶Cardiology Department Kings College, London, United Kingdom..

Published: 27 January 2016

doi:10.1186/1532-429X-18-S1-Q37

Cite this article as: Obianyo *et al.*: It's not just the mitral valve - abnormal motion of the whole aorto-mitral apparatus occurs in both overt and subclinical hypertrophic cardiomyopathy. *Journal of Cardiovascular Magnetic Resonance* 2016 **18**(Suppl 1):Q37.

**Submit your next manuscript to BioMed Central
and take full advantage of:**

- Convenient online submission
- Thorough peer review
- No space constraints or color figure charges
- Immediate publication on acceptance
- Inclusion in PubMed, CAS, Scopus and Google Scholar
- Research which is freely available for redistribution

Submit your manuscript at
www.biomedcentral.com/submit

