

CORRECTION

Open Access



Correction to: Imaging of the pulmonary vasculature in congenital heart disease without gadolinium contrast: Intraindividual comparison of a novel Compressed SENSE accelerated 3D modified REACT with 4D contrast-enhanced magnetic resonance angiography

Lenhard Pennig^{1*}, Anton Wagner¹, Kilian Weiss², Simon Lennartz^{1,3}, Jan-Peter Grunz⁴, David Maintz¹, Kai Roman Laukamp¹, Tilman Hickethier¹, Claas Philip Naehle¹, Alexander Christian Bunck¹ and Jonas Doerner¹

Correction to: J Cardiovasc Magn Reson

<https://doi.org/10.1186/s12968-019-0591-y>

The original publication of this article [1] contained displaced depiction of confidence intervals within the Bland-Altman plots in Figs. 1 and 2, which have been adjusted. Additionally, the corresponding titles of the plots were interchanged in the initial version of the manuscript and have been corrected accordingly. The updated figures (Figs. 1 and 2) are published in this corrected article.

comparison of a novel compressed SENSE accelerated 3D modified REACT with 4D contrast-enhanced magnetic resonance angiography. *J Cardiovasc Magn Reson.* 2020;22:8. <https://doi.org/10.1186/s12968-019-0591-y>.

Author details

¹Institute for Diagnostic and Interventional Radiology, Faculty of Medicine and University Hospital Cologne, University of Cologne, Kerpener Straße 62, 50937 Cologne, Germany. ²Philips GmbH, Hamburg, Germany. ³Else Kröner Forschungskolleg Clonal Evolution in Cancer, University Hospital Cologne, Weyertal 115b, 50931 Cologne, Germany. ⁴Department of Diagnostic and Interventional Radiology, University Hospital Würzburg, Oberdürrbacher Straße 6, 97080 Würzburg, Germany.

Published online: 21 February 2020

Reference

1. Pennig L, Wagner A, Weiss K, et al. Imaging of the pulmonary vasculature in congenital heart disease without gadolinium contrast: Intraindividual

The original article can be found online at <https://doi.org/10.1186/s12968-019-0591-y>

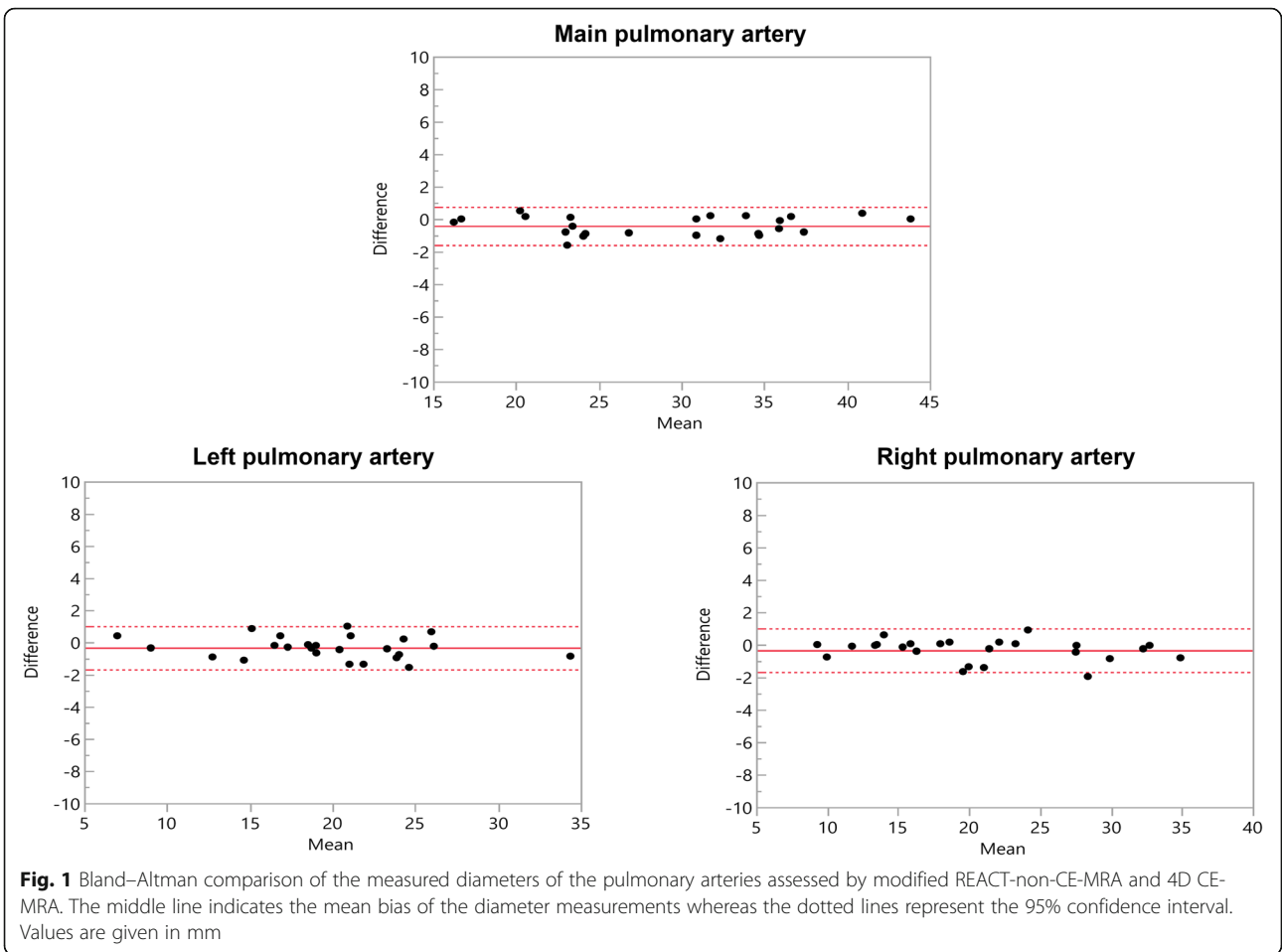
* Correspondence: Lenhard.pennig@uk-koeln.de

¹Institute for Diagnostic and Interventional Radiology, Faculty of Medicine and University Hospital Cologne, University of Cologne, Kerpener Straße 62, 50937 Cologne, Germany

Full list of author information is available at the end of the article



© The Author(s). 2020 **Open Access** This article is distributed under the terms of the Creative Commons Attribution 4.0 International License (<http://creativecommons.org/licenses/by/4.0/>), which permits unrestricted use, distribution, and reproduction in any medium, provided you give appropriate credit to the original author(s) and the source, provide a link to the Creative Commons license, and indicate if changes were made. The Creative Commons Public Domain Dedication waiver (<http://creativecommons.org/publicdomain/zero/1.0/>) applies to the data made available in this article, unless otherwise stated.



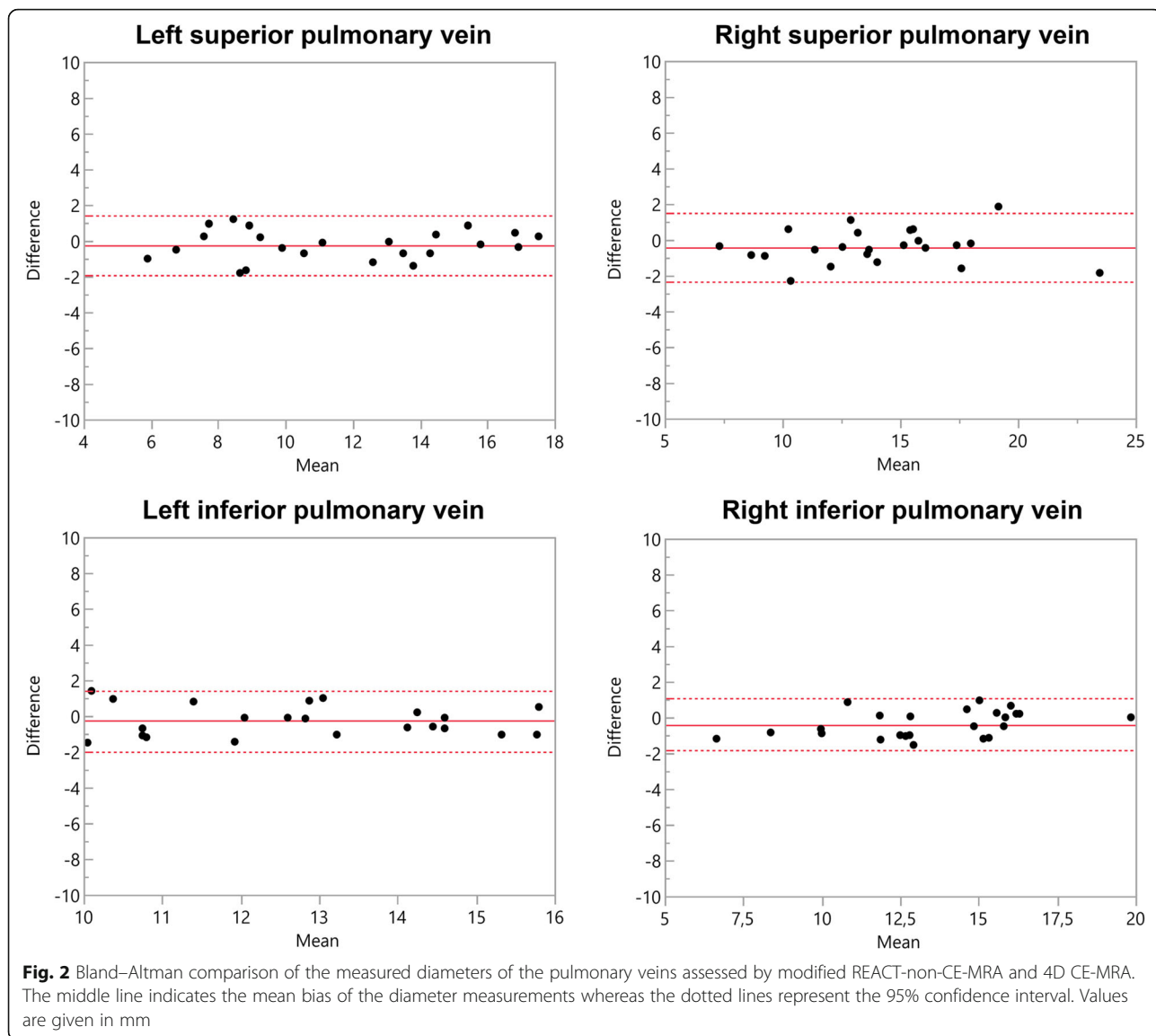


Fig. 2 Bland–Altman comparison of the measured diameters of the pulmonary veins assessed by modified REACT-non-CE-MRA and 4D CE-MRA. The middle line indicates the mean bias of the diameter measurements whereas the dotted lines represent the 95% confidence interval. Values are given in mm